

2015 EUROPEAN CANCER CONGRESS

25-29 September 2015

Vienna, Austria

SUMMARY

The European Cancer Congress (ECC 2015) combined the 40th European Society for Medical Oncology (ESMO) congress with the 18th congress of the European CanCer Organisation (ECCO) and was held 25 to 29 September, 2015. The meeting was organised in partnership with the European Society of Radiation and Oncology (ESTRO), the European Society of Surgical Oncology (ESSO), the European Academy for Cancer Research (EACR), the European Oncology Nursing Society (EONS), and International Society of Paediatric Oncology (SIOPE). The efforts of all partner organisations were united to continue advancing multidisciplinary as the way forward to optimise the prevention, diagnosis, treatment, and care of cancer patients by encouraging participants to leverage knowledge, promote education and build awareness for patient-centred oncology.

Contents

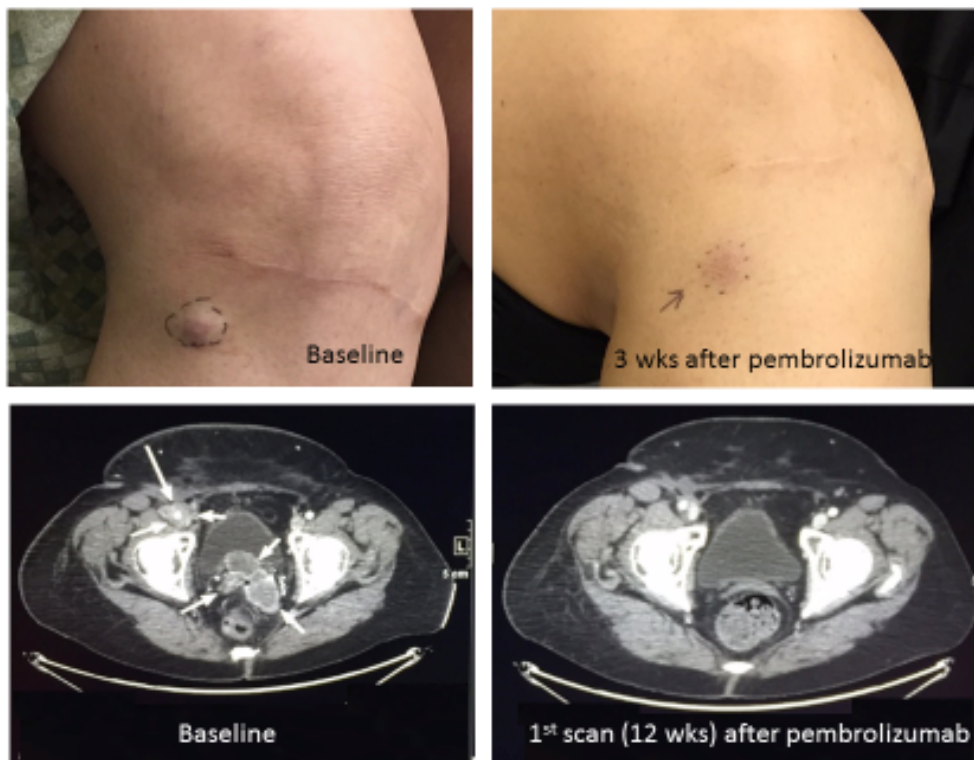
SUMMARY.....	1
Contents.....	2
IMMUNOTHERAPY FOR CANCER.....	3
Blocking PD1 with pembrolizumab shows promise in patients with Merkel cell carcinoma.....	3
Significant PD-L2 expression detected in varied human tumour types.....	5
Pneumonitis reported during anti-PD-1/PD-L1 therapy has varied subtypes.....	6
Immune infiltrate changes with PD1 inhibition associate with response in patients with melanoma.....	7
Related information.....	10
Affiliation and Disclosure.....	10
Affiliation.....	10
Disclosure.....	10
Acknowledgment.....	10

IMMUNOTHERAPY FOR CANCER

Blocking PD1 with pembrolizumab shows promise in patients with Merkel cell carcinoma

The first report of PD-1 blockade in Merkel cell carcinoma (MCC) was made by Paul Nghiem, Fred Hutchinson and Cancer Research Center, Seattle, USA on behalf of colleagues from the Cancer Immunotherapy Trials Network (CITN) and the US NCI's Cancer Therapy Evaluation Program (CTEP). He explained that, although MCC has been historically difficult to treat, MCC tumours express PD-L1, providing an immunotherapeutic target that could make them responsive to PD1 blockade with pembrolizumab. The investigators evaluated pembrolizumab as first systemic therapy in patients with advanced MCC in an open-label, single arm, Simon two-stage trial that could expand to include 24 patients if at least one response was observed among the first 9 patients. The trial enrolled 18 patients with MCC and good performance status, and who were not immune suppressed or did not have autoimmune disease, to receive pembrolizumab at 2 mg/kg every 3 weeks; response (RECIST 1.1) assessments were done every 9 to 12 weeks.

At least one radiologic and clinical response assessment has been done thus far in 10 of the patients enrolled that revealed a 71% response rate. Complete response (CR) was achieved by one patient, and one patient had an unconfirmed CR (uCR). Partial response (PR) was observed in 4 patients and 2 patients have an unconfirmed PR. With pembrolizumab, 2 patients with MCC experienced disease progression and have discontinued the study. The remaining 8 treated patients have not yet had initial scans; however, 3 patients with clinically measurable disease have shown regression of clinically evaluable lesions following pembrolizumab, although visceral disease status awaits radiologic evaluation.



Caption: A 70 year old woman developed metastatic Merkel cell carcinoma (MCC) involving the abdomen and pelvis as well as right thigh skin metastases (one lesion shown at top left). Pelvic metastases (bottom left, indicated by arrows) led to bladder compression and urinary frequency.

One week after an initial dose of pembrolizumab (2mg/kg) urinary frequency resolved and the lesions on the leg regressed. The leg lesion (top right) was biopsied at week 3 and showed a robust lymphocytic infiltrate with no residual MCC tumor cells by immunohistochemistry.

A restaging scan at week 13 (after 4 doses of pembrolizumab) showed complete resolution of the posterior wall mass of the urinary bladder (bottom right) and overall a >50% regression per RECIST. She continues to receive treatment on trial without side effects and her tumours continue to decrease in size.

Credit: Paul Nghiem.

Adverse events included grade 4 myocarditis in one patient after the first dose, and one patient had grade 4 transaminase elevation after receiving 2 doses; both patients improved with steroid treatment after the study drug was discontinued. Interestingly, both of these patients demonstrated

favourable tumour responses, with one patient showing regression of skin metastases, while the other patient continues to show an ongoing PR of extensive visceral The authors noted that 8 of the 10 patients evaluated following pembrolizumab monotherapy as the first systemic intervention have shown evidence (5 confirmed and 3 unconfirmed by subsequent scans) of response to PD-1 pathway blockade and 3 of 3 additional patients with clinically evaluable metastases have shown clinical regression of tumours (prior to first scan). The investigators speculated that this high response rate may partly be due to the immune response to antigens in the tumour from the polyomavirus that often drives MCC. Of the 18 patients enrolled, 14 continue to receive anti-PD-1 on trial. The authors concluded that reporting these data may benefit patients with this aggressive cancer by encouraging accelerated clinical testing of PD-1 blocking agents in MCC. Nghiem *et al.* Abstract 22LBA.

Practice point and future research opportunities

While these data are still early, these results are very promising, especially in such a rare and difficult-to-treat disease where there is a high medical need for novel therapies. The findings include a high objective response rate and the responses are especially noteworthy given the difficulty in treating MCC, which often evades the patient's immune response, making durable responses to chemotherapy in the metastatic setting difficult to achieve with progression-free survival rates of around just 90 days commonly observed. PD-1 blockade is a promising treatment that warrants further investigation in Merkel cell carcinoma, among other cancer types.

Significant PD-L2 expression detected in varied human tumour types

Jennifer H. Yearley, Merck & Company Inc., Kenilworth, USA discussed the significance of PD-L2 expression and how it may allow broader use of PD-1 targeting agents in the treatment of an expanded range of human tumour types. Biomarker screening by immunohistochemistry (IHC) done prior to administering PD-1 targeting agents to determine whether the tumour type is a candidate for treatment with these agents has revealed some PD-L1–negative patients that have responded to PD-1 targeted therapies, possibly via tumour expression of the other known ligand, PD-L2. Therefore, Yearly and colleagues investigated the expression of PD-L2 in different tumour types and evaluated the potential role it may play regarding clinical responsiveness to anti-PD-1 therapies. They used a novel IHC assay for PD-L2 on groups of archival tissue from 7 human tumour types, including renal cell carcinoma (RCC), bladder carcinoma, melanoma, non-small cell lung cancer (NSCLC), head and neck squamous carcinoma (HNSC), triple-negative breast cancer (TNBC), and gastric carcinoma. Sample sizes of the groups evaluated ranged from 22 tissue

samples in TNBC to 94 samples in NSCLC, with a median sample size of 71 samples per tumour type. The findings of PD-L2 IHC staining was also compared with PD-L2 mRNA levels, as determined using the Nanostring platform, and with results obtained using PD-L1 IHC staining.

This study demonstrated that PD-L2 expression within the tumour microenvironment can be significant in these 7 tumour types. A significant association was determined between the extent and distribution of PD-L2 IHC labelling and the extent and distribution of PD-L1 IHC labeling (range: $p = 0.0012$ to $p < 0.0001$). PD-L2 expression was also shown to significantly correlate with levels of PD-L2 mRNA in the tumour samples, (range: $p = 0.0037$ to $p < 0.0001$).

Discordant expression was also observed: Individual tumour samples showed PD-L1 expression in the absence of PD-L2, while other tumour samples showed the reverse. Therefore, the authors suggest that screening for both biomarkers may best guide the selection in PD-1 axis targeting agents. They also summarised that PD-L2 expressed within human tumours in the absence of PD-L1 may provide an alternate target for agents directed to the PD-1 pathway, and at least partially account for PD-L1–negative patients having a positive clinical response to anti-PD-1 targeted therapies. Yearly *et al.* Abstract 18LBA.

Practice point and future research opportunities

Treatment with drugs targeting the PD-1 axis has resulted in groundbreaking improvements in clinical response in multiple human cancers. Biomarker screening prior to initiation of PD-1 axis-targeted treatments has focused on evaluation of tumour expression of PD-L1, a known ligand of PD-1. However, this study showed another ligand, PD-L2, is expressed within human tumours and determined the prevalence and distributional properties of PD-L2 in multiple cohorts of archival human tumours and has shown significant expression of PD-L2 in 7 cancer types. These findings suggest some patients populations may benefit from anti-PD-1 targeted therapies blocking both interactions but who might not experience benefit from an agent targeting just PD-L1. PD-L2 expression may also, in part, explain the response to anti-PD-1 agents reported in PD-L1 negative patients screening for both ligands is warranted.

Pneumonitis reported during anti-PD-1/PD-L1 therapy has varied subtypes

Pneumonitis is a rare but potentially fatal side effect of immune checkpoint antibodies targeting the PD-1/PD-L1 pathway, according to lead author Jarushka Naidoo, Johns Hopkins, Baltimore, USA, who also pointed out that the clinical and radiographic features of immune-related pneumonitis associated with these agents are poorly described. This study reviewed clinicopathological data from 653 patients receiving an anti-PD-1/PD-L1 monoclonal antibody, either alone or in

combination, while participating in a clinical trial from 2009 to 2014. Chest computed tomography (CT) scans of all patients were independently assessed by 2 radiologists by describing the radiologic features throughout clinical course of pneumonitis, grading each case as mild/moderate/severe, and reassessing the CT scans together to create a 'consensus read'.

In all, 36 (6%) patients reported an adverse event (AE) of pneumonitis within 11 different therapeutic protocols. The median age of these patients was 63 (range: 34 to 78) years, and 23 (64%) were former/current smokers. Most patients developing pneumonitis received PD-1/PD-L1 therapy as part of a combination; 14 (39%) patients received anti-PD-1/PD-L1 monotherapy whereas 22 (61%) patients received combination therapy. Of these, 33 (92%) patients received an anti-PD-1 monoclonal antibody, 3 (8%) received an anti-PD-L1 monoclonal antibody.

Standard radiologic assessment criteria identified 5 distinct subtypes of pneumonitis: Chronic obstructive pneumonia (COP)-like was reported in 7 (19%) patients, ground-glass opacifications (GGO) in 13 (36%), hypersensitivity-type in 7 (19%), interstitial-type in 4 (11%) patients and pneumonitis not-otherwise-specified (NOS) was identified in 5 (14%) of pneumonitis patients. Subtypes of pneumonitis were found to generally associate with the site of primary cancer: COP-like pneumonitis was reported in 6 patients with lung cancer but just one patient with haematologic malignancies and GGO was most often seen in melanoma ($p = 0.025$). Pneumonitis hypersensitivity-type, interstitial-type and NOS were distributed across cancer subtypes. COP-like pneumonitis compared to other subtypes, showed a trend towards association with the development of grade 3plus toxicity ($p = 0.052$) and with the requirement for more than one type of immunosuppression ($p = 0.093$). The authors summarised that pneumonitis reported as an AE following anti-PD-1/PD-L1 therapies may display a variety of radiologic appearances and these radiologic subtypes may associate with the primary cancer site, with COP-like pneumonitis possibly more clinically aggressive. Naidoo *et al.* Abstract 503.

Practice point and future research opportunities

These findings may help clinicians to identify the rare but potentially fatal adverse event of pneumonitis following anti-PD-1/PD-L1 therapies, and have particular relevance in lung cancer and melanoma, where these agents have been recently approved for use in the clinic.

Immune infiltrate changes with PD1 inhibition associate with response in patients with melanoma

Ricardo Vilain, Melanoma Institute Australia, Sydney, Australia, reported on changes observed in tumoural PD-L1 expression and tumour-associated immune cell flux in melanoma patients undergoing treatment with immune checkpoint inhibitors. Although checkpoint inhibitors have demonstrated improved survival in metastatic melanoma patients by disrupting PD-L1/cytotoxic T-cell PD1 signalling, little else is known about these treatments. To characterise PD-L1 expression in patients undergoing treatment with checkpoint inhibitors, this study analysed 49 tumour biopsies from 24 patients with unresectable AJCC stage III/IV metastatic melanoma; 21 biopsies each had been collected prior to (PRE) and within two months of commencing treatment (EDT), whereas 7 were taken upon disease progression (PROG).

The best response (RECIST or iRC criteria) following pembrolizumab or nivolumab was correlated with the histomorphological and immunohistochemical analysis; a complete response (CR) was achieved by one patient, 6 patients showed partial response (PR), and 9 patients had stable disease. In the PRE biopsies, intra-tumoural and peri-tumoural density of PD1-positive T-cells was 8.1-fold higher ($p = 0.0142$) and 6.8-fold higher ($p = 0.0098$), respectively, in responding patients. Furthermore, the PRE intra-tumoural and peri-tumoural density of PD1-positive T-cells significantly associated with the degree of tumour shrinkage on radiology ($r = -0.356$, $p = 0.0090$) and ($r = -0.442$, $p = 0.0035$), respectively. Analysis of the EDT biopsies revealed a significant influx of intra-tumoural CD3+, CD8+ and CD68+ macrophages during treatment in responders that was not seen in non-responders. Also, during treatment, responders showed a higher distribution of PD-L1 expression on tumour cells ($p = 0.0554$) and on macrophages ($p = 0.0379$). Analysis of biopsies from patients progressing during treatment revealed that PD-L1 expression was present in both the tumour and macrophage cell components and a trend for increased intra-tumoural and peri-tumoural macrophage density was observed.

The authors concluded that the higher numbers of PD1-positive T-cells in the PRE biopsies of responders suggests the active suppression of the immune response, which was disrupted by anti-PD1 therapies and that the increased PD-L1 expression seen in the EDT biopsies of responders likely reflects disengagement of the PD-L1/PD1 axis, reactivation of PD1positive T-cells and increased interferon- γ production. The biopsies from the patients with progressive disease suggest the acquisition of resistance to PD1 inhibition, and the lack of changes in PD-L1 expression or T-cell infiltrates suggests other mechanisms are involved in immune escape. Vilain *et al.* Abstract 3305.

Practice point and future research opportunities

This analysis of biopsies taken prior to and during treatment with pembrolizumab and nivolumab reflected changes in PD-L1 expression and changes in the cells in the tumour environment. Patients responding to treatment showed an association with higher PD-1 expression on T cells surrounding the tumour prior to treatment and increased macrophage infiltration plus increased PD-1-positive expression on tumour cells and macrophages during treatment, whereas PD-L1 was uniformly expressed on tumour and macrophages in the biopsies of patients progressing on treatment. These intriguing results should be confirmed and expanded upon in analyses of larger number of biopsy samples from larger trials.

RELATED INFORMATION

[Click here to access Congress details and programme.](#)

[Click here to access the Congress webcast page.](#)

AFFILIATION AND DISCLOSURE

Affiliation

Dr Svetlana Jezdic, ESMO Head Office.

Disclosure

No conflicts of interest to disclose.

ACKNOWLEDGMENT

ESMO would like to thank Virginia Powers, PhD for editorial assistance in preparation of the report.

ESMO would like to thank Drs Jeffrey Ross, Siraj Ali, Christoph Zielinski, Eva Segalov, Toni Choueiri, Richard Cathomas, Paul Nghiem, James Yao, Grant McArthur, and Rolf Issels for giving their permission to publish images from the studies presented during the ECC 2015 in the ESMO media channels.