

## Tumours of the kidney

>95% of kidney cancers have a **characteristic morphology** that can be classified as: clear cell, papillary and chromophobe renal cell carcinoma (RCC), and collecting duct carcinoma.

A small proportion of rare kidney cancer entities are defined on a molecular basis, e.g. the **microphthalmia transcription factor (MiT) family translocation RCC** and succinate dehydrogenase-deficient RCC.

A 2018 study from Carlo et al showed a **high prevalence of cancer-associated germline mutations in advanced kidney cancers** (especially in non-clear cell RCC: 11.7% RCC-associated gene mutations).

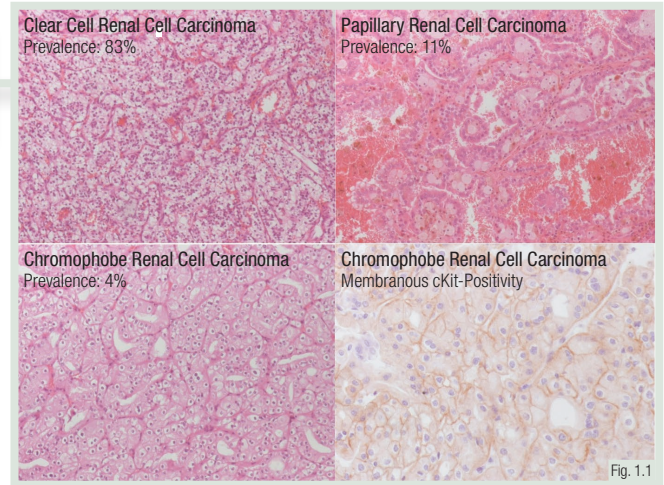


Fig. 1.1

### Clinical and pathological classification of the primary tumour (pT)

<b>T1</b>	Tumour 7 cm or less in greatest dimension, limited to the kidney
<b>T2</b>	Tumour more than 7 cm in greatest dimension, limited to the kidney
<b>T3</b>	Tumour extends into major veins or perinephric tissues
<b>T4</b>	Tumour invades beyond Gerota fascia

Fig. 1.2

**Pathological tumour stage** has a strong prognostic impact.

In the past, various grading systems (e.g. Thoenes or Fuhrmann) have been used for **RCC staging**. Today, the World Health Organization/International Society of Urological Pathology (**WHO/ISUP**) four-tiered system should be applied.

Tumour grade is defined mainly on the basis of **nucleolar prominence**.

5%-7% of kidney tumours are benign. **Oncocytoma** is the most frequent benign kidney tumour. The tumour is well circumscribed, mahogany brown with a central scar.

**Angiomyolipomas** represent 1% of kidney tumours. They consist of varying proportions of mature fat, thick-walled blood vessels and smooth muscle.

**Multilocular cystic renal neoplasm of low malignant potential** is in principle a malignant tumour, but is entirely composed of cysts, with very few cancer cells. Metastases have not been reported.

### 'Benign' renal tumours

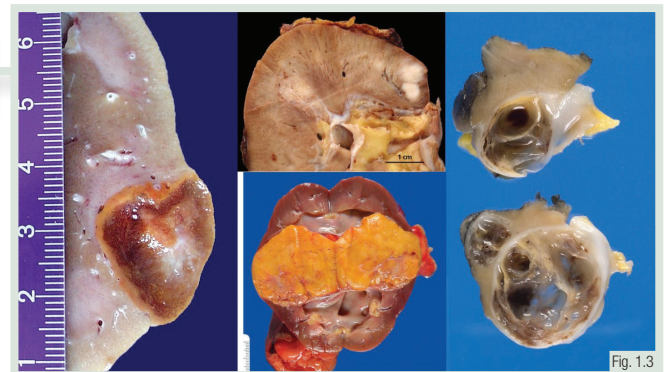


Fig. 1.3

Oncocytoma

Angiomyolipoma

Multilocular cystic renal cell carcinoma

## REVISION QUESTIONS

1. What are the main subtypes of RCC?
2. What is the best predictor of prognosis in RCC?
3. Which carcinoma has the best prognosis?

## Tumours of the urinary system

**Urothelium** is present in the kidney pelvis, ureters, urinary bladder and the urethra.

Urothelial neoplasms can occur in **all of these organs** but more than 90% are located in the urinary bladder.

The normal **bladder wall** consists of several tissue layers, the distinction of which is critical for bladder cancer staging.

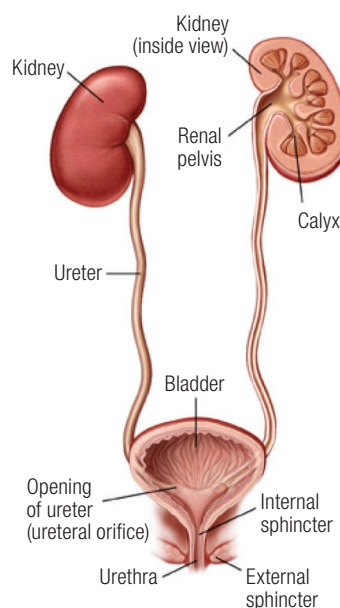


Fig. 1.4

Diagram showing the T stages of bladder cancer

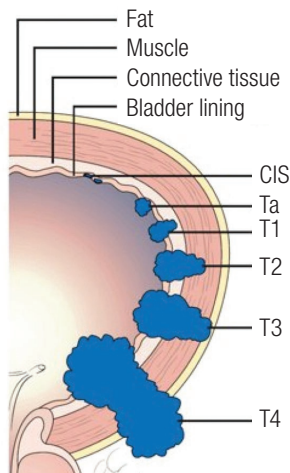


Fig. 1.5

CIS, carcinoma *in situ*.

The urothelium covers the inner surface of the bladder. The connective tissue layer between the urothelium and the muscular bladder wall is the **lamina propria**.

The **staging system** of urothelial neoplasms is unusual, as **two non-invasive types of lesions** exist: non-invasive papillary carcinoma (pTa) and carcinoma *in situ* (pTis).

The **invasive stages** are pT1: invasion of lamina propria; pT2: invasion of muscular wall; pT3: invasion of perivesical fat and pT4: invasion of adjacent organs.

Staging of bladder neoplasms is critical for treatment decisions, but **challenging for pathologists**.

This is due to the nature of transurethral tumour resection, because it always leads to **fragmentation and to substantial crush artefacts** in the resected tissues.

The distinction between **pTa and pT1 tumours** can be very challenging and is subject to high interobserver variability.

pTa versus pT1: High interobserver variability

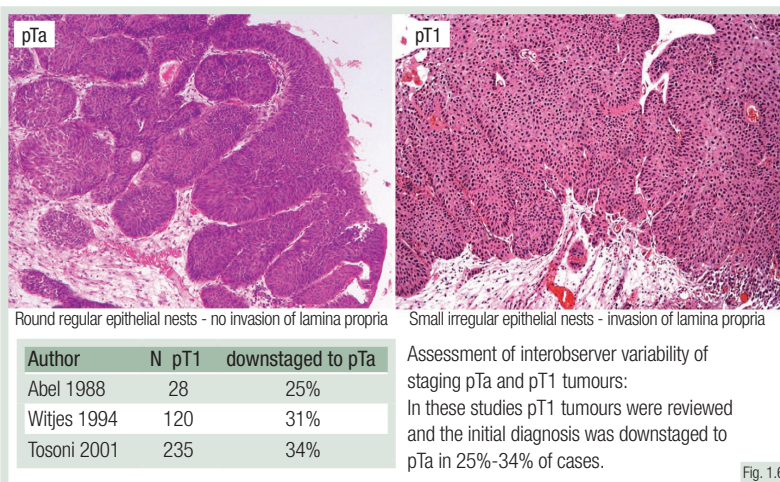


Fig. 1.6

### REVISION QUESTIONS

1. What is the most common site for urothelial cancer?
2. What is the difference between stages pTa and pTis?
3. Which tumour stages are subject to particularly high interobserver variability?

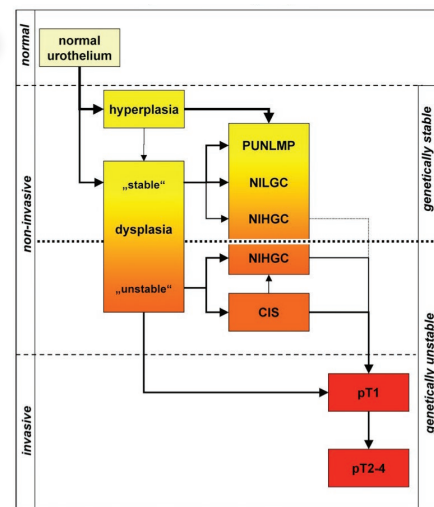
## Tumours of the urinary system (continued)

Development and progression of urothelial neoplasia occurs through **two quite different genetic pathways**.

**Non-invasive papillary cancers** of low/intermediate grade (pTa, G1/2) develop from dysplasia/hyperplasia and almost never progress to invasive cancer.

**Invasive carcinomas** are mostly of high grade and are mainly derived from carcinoma *in situ* or high-grade non-invasive papillary carcinomas (pTa, G3).

Model of bladder cancer development and progression based on genetic findings



CIS, carcinoma *in situ*; NIHGC, non-invasive high-grade carcinoma; NILGC, non-invasive low-grade carcinoma; PUNLMP, papillary urothelial neoplasm of low malignant potential.

Fig. 1.7

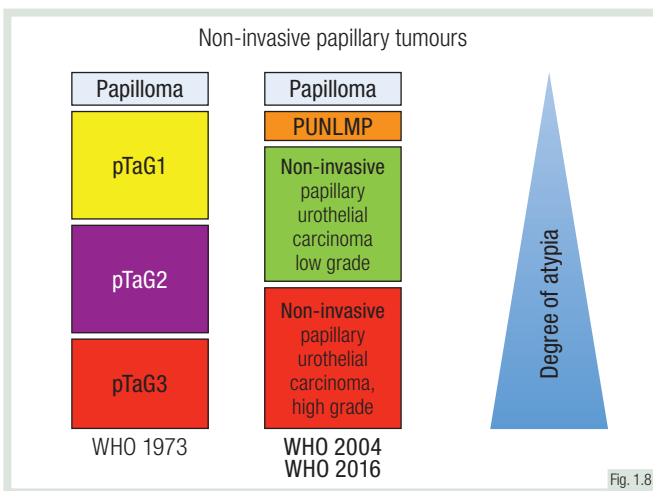


Fig. 1.8

PUNLMP, papillary urothelial neoplasm of low malignant potential; WHO, World Health Organization.

The classification of non-invasive papillary carcinomas is confusing because **two 'non-congruent' systems** are typically used, either alone or in parallel.

Most clinicians are familiar with the **WHO 1973** grading system, which classifies non-invasive cancers as pTaG1, pTaG2 or pTaG3.

The **WHO 2004** version (also adopted in the WHO 2016 version) also includes: papilloma, papillary urothelial neoplasm of low malignant potential (PUNLMP), low-grade non-invasive papillary cancer and high-grade non-invasive bladder cancer.

The clinical term '**non-muscle invasive bladder cancer**' is used for pTa and pT1 tumours.

pTa and pT1 tumours not only represent two different entities at the genetic level, but also have a completely **different clinical course**.

While pTa tumours rarely progress, **pT1 tumours are early stages of highly malignant neoplasms**.

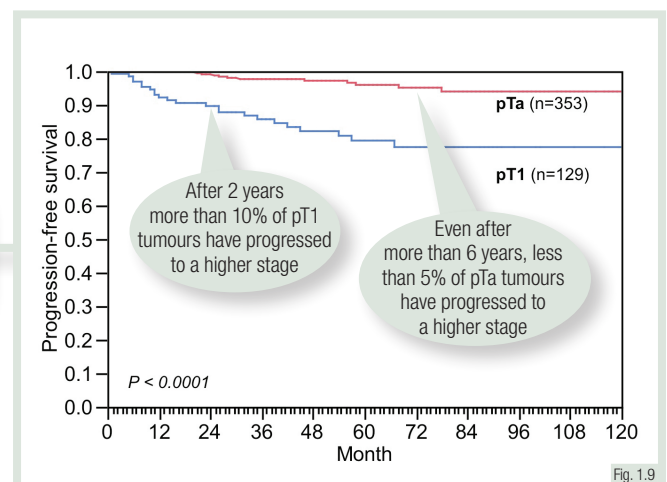


Fig. 1.9

### REVISION QUESTIONS

1. What are the two main groups of urothelial neoplasms?
2. What is the difference between the WHO 1973 and WHO 2004/2016 classifications?
3. Why should the term 'superficial bladder cancer' be avoided?

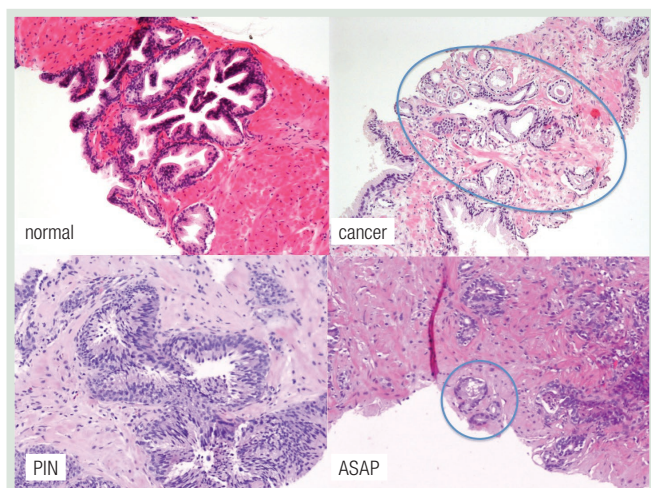
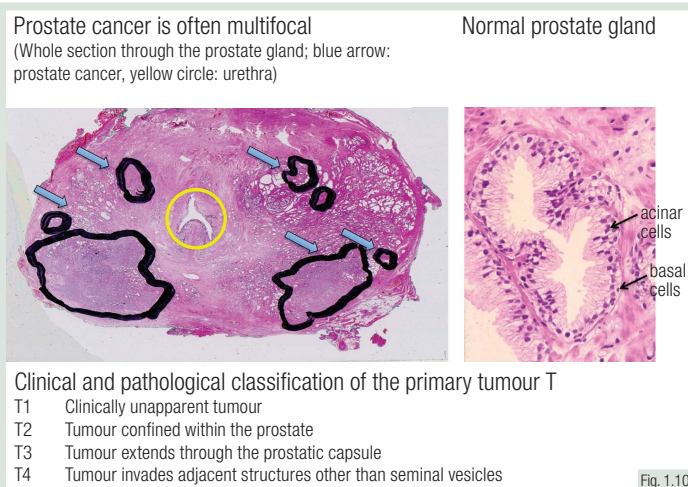


## Tumours of the prostate

**Prostate cancer (PC)** is very common. A complete examination of the prostate will reveal cancer in 50% of men at the age of 50 and >75% at the age of 75 years.

Accordingly, **precursor lesions** are even more common in the prostate and many patients have more than one spatially separated PC.

**Normal prostate epithelium** is characterised by the presence of two cell layers: basal cells and acinar cells.



ASAP, atypical small acinar proliferation; PIN, prostatic intraepithelial neoplasia.

Prostate biopsy is the only tool for establishing a **definitive diagnosis** of PC.

Findings in **prostate biopsies** include: normal, prostatic intraepithelial neoplasia (PIN), atypical small acinar proliferation (ASAP) and carcinoma.

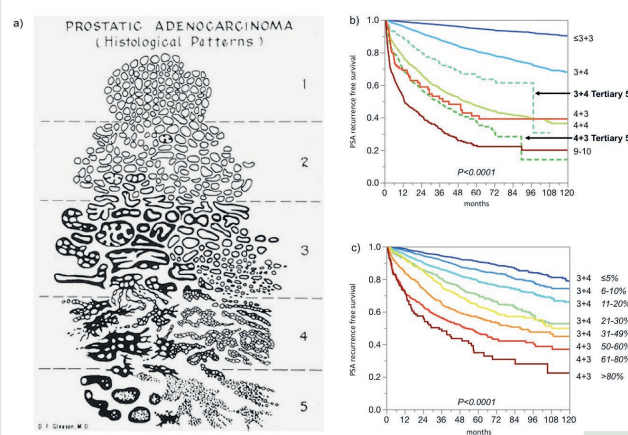
PIN is the precursor lesion of PC. **ASAP** is a diagnostic category that includes all changes that are suspicious for cancer but not unequivocally diagnostic.

PC is entirely composed of atypical cells, while basal cells are completely lost. **Gleason grade** is the strongest predictor of tumour aggressiveness.

In contrast with all other grading systems, the Gleason grade is based solely on **tumour architecture** and does not consider any cytological changes.

The **Gleason score** is defined as the sum of the two most common grade patterns. The traditional Gleason grading system only distinguishes 5 groups:  $\leq 6$ , 3+4, 4+3, 8, 9-10, also termed **ISUP grade groups 1-5**. The use of tertiary grades or the percentage of Gleason 4/5 offers a finer assessment of cancer aggressiveness.

a) The original Gleason grading system diagram. b) and c) Impact of the Gleason pattern on patient prognosis (time to biochemical recurrence).



PSA, prostate-specific antigen.

### REVISION QUESTIONS

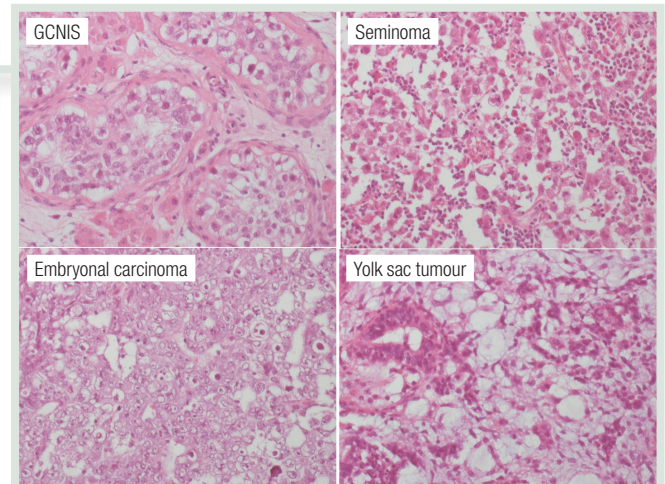
1. What is the precursor lesion of PC?
2. What is the meaning of 'ASAP' and when is this term used?
3. What is the characteristic of Gleason grading?

## Tumours of the testis

More than 95% of all testicular neoplasias are **germ cell tumours (GCTs)**. GCTs mostly occur at young age (peak frequency at the age of 30 years).

More than 90% of GCTs develop through **germ cell neoplasia *in situ* (GCNIS)**, formerly called **intratubular germ cell neoplasia, unclassified (IGCNU)**, which is commonly found in the vicinity of these cancers.

50% of GCNIS progress to **invasive GCTs** within 5 years, and at least 70% within 7 years.



GCNIS, germ cell neoplasia *in situ*.

Fig. 1.13

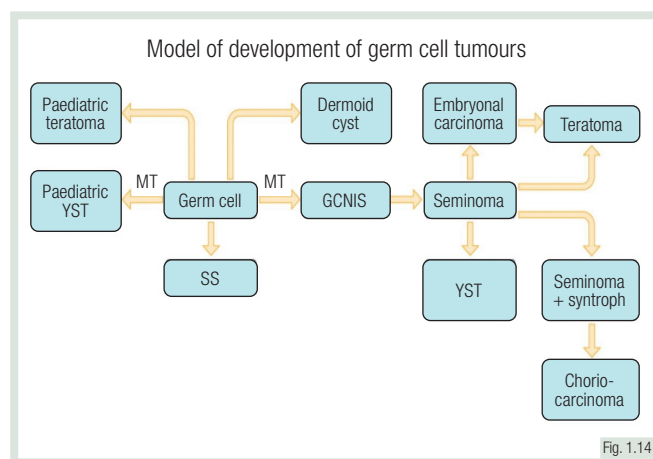


Fig. 1.14

GCNIS, germ cell neoplasia *in situ*; MT, malignant transformation; SS, spermatocytic seminoma; YST, yolk sac tumour.

**Tumour stage (pT)** is critical for subsequent therapy of testicular tumours.

Most pT2 stages are diagnosed because of **vascular invasion**.

**Regional lymph nodes** include the abdominal, para-aortic, pre-aortic, interaortocaval, precaval, paracaval, retrocaval and retroaortic lymph nodes.

**Seminoma** is the earliest development stage of invasive GCT.

About 50% of all testicular GCTs halt at that stage of development and are diagnosed as **pure seminomas**.

**Teratoma** in the adult is a 'differentiated type' of GCT having evolved from GCNIS and seminoma. Teratoma in adults is thus considered malignant.

### Clinical and pathological classification of the primary tumour T

- |           |   |
|-----------|---|
| <b>T1</b> | Tumour limited to testis and epididymis <u>without</u> vascular/lymphatic invasion  |
| <b>T2</b> | Tumour limited to testis and epididymis <u>with</u> vascular/lymphatic invasion or tumour extending through tunica albuginea with involvement of tunica vaginalis |
| <b>T3</b> | Tumour invades spermatic cord   |
| <b>T4</b> | Tumour invades scrotum  |

Fig. 1.15

## REVISION QUESTIONS

1. What is the precursor lesion of most GCTs?
2. What is the typical age of diagnosis for GCT?
3. Why is a testicular teratoma in an adult considered malignant?

## Summary: Anatomy of the genitourinary tract and histology of genitourinary tumours

- The most common kidney cancers are clear cell, papillary and chromophobe RCC
- Urothelium is present in the renal pelvis, ureters, urinary bladder and urethra, but >90% of urothelial neoplasms occur in the urinary bladder
- The staging system of urothelial neoplasms is unusual as two types of non-invasive lesions exist: pTa and pTis
- There is a high interobserver variability in staging pTa and pT1 tumours
- pTa and pT1 tumours represent two different entities at the genetic level and have a completely different clinical course
- PC is very common and will be found upon examination in >75% of men at the age of 75 years
- PC is graded according to Gleason grading, the strongest predictor of tumour aggressiveness. Since 2014, the ISUP grading system is also used
- More than 95% of all testicular neoplasias are GCTs
- GCTs mostly occur at young age
- GCTs include seminoma, embryonal carcinoma, yolk sac tumour, choriocarcinoma and teratoma

## Further Reading

Carlo MI, Mukherjee S, Mandelker D, et al. Prevalence of germline mutations in cancer susceptibility genes in patients with advanced renal cell carcinoma. *JAMA Oncol* 2018; 4:1228–1235.

Delahunt B, Eble JN, Egevad L, Samaratunga H. Grading of renal cell carcinoma. *Histopathology* 2019; 74:4–17.

Epstein JI, Allsbrook WC Jr, Amin MB, Egevad LL; ISUP Grading Committee. The 2005 International Society of Urological Pathology (ISUP) Consensus Conference on Gleason Grading of Prostatic Carcinoma. *Am J Surg Pathol* 2005; 29:1228–1242.

Epstein JI, Egevad L, Amin MB, et al; Grading Committee. The 2014 International Society of Urological Pathology (ISUP) consensus conference on Gleason grading of prostatic carcinoma: definition of grading patterns and proposal for a new grading system. *Am J Surg Pathol* 2016; 40:244–252.

Idrees MT, Ulbright TM, Oliva E, et al; Members of the International Society of Urological Pathology Testicular Tumour Panel. The World Health Organization 2016 classification of testicular non-germ cell tumours: a review and update from the International Society of Urological Pathology Testis Consultation Panel. *Histopathology* 2017; 70:513–521.

Moch H, Humphrey PA, Ulbright TM, Reuter VE. WHO Classification of Tumours of the Urinary System and Male Genital Organs, fourth edition. Lyon: International Agency for Research on Cancer (IARC); 2016.

Sauter G, Clauditz T, Steurer S, et al. Integrating tertiary Gleason 5 patterns into quantitative Gleason grading in prostate biopsies and prostatectomy specimens. *Eur Urol* 2018; 73:674–683.

Sauter G, Mihatsch MJ. Pussycats and baby tigers: non-invasive (pTa) and minimally invasive (pT1) bladder carcinomas are not the same! *J Pathol* 1998; 185:339–341.

Srigley JR, Delahunt B, Eble JN, et al; ISUP Renal Tumour Panel. The International Society of Urological Pathology (ISUP) Vancouver Classification of Renal Neoplasia. *Am J Surg Pathol* 2013; 37:1469–1489.

Tosoni I, Wagner U, Sauter G, et al. Clinical significance of interobserver differences in the staging and grading of superficial bladder cancer. *BJU Int* 2000; 85:48–53.

Williamson SR, Delahunt B, Magi-Galluzzi C, et al; Members of the ISUP Testicular Tumour Panel. The World Health Organization 2016 classification of testicular germ cell tumours: a review and update from the International Society of Urological Pathology Testis Consultation Panel. *Histopathology* 2017; 70:335–346.