

Nely Mercy Díaz Mejía  
Medical Oncology Resident  
Vall d'Hebron University Hospital

***Geriatric gastric cancer: Pembrolizumab as an option in MSI patients.***

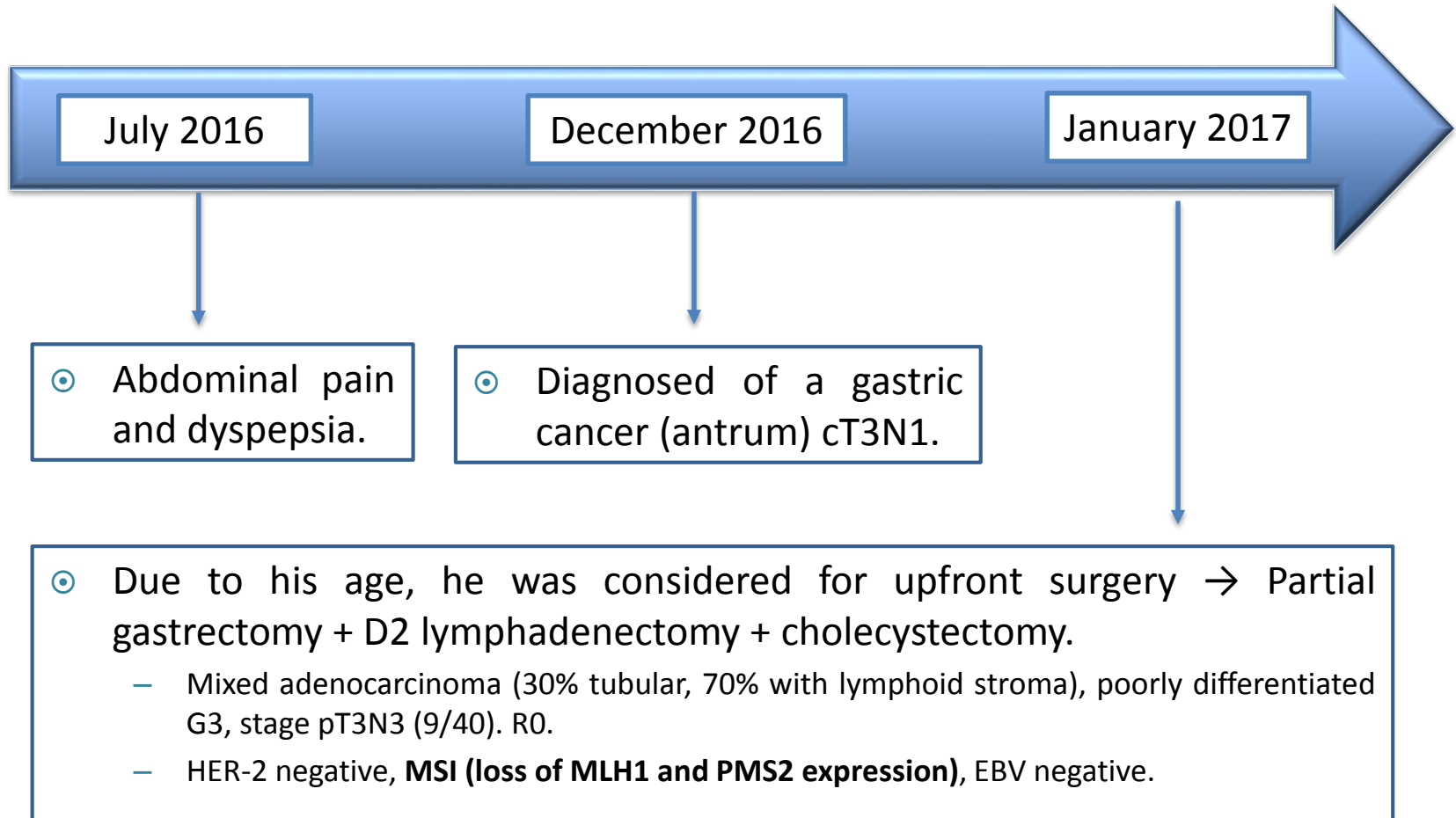
# DISCLOSURE OF INTEREST

- ◉ No disclosures of interest.

# MEDICAL HISTORY

- ⦿ 83 year old male.
- ⦿ No allergies.
- ⦿ Former smoker.
- ⦿ Hypertension.
- ⦿ Prostate cancer (i.s.) 2014 → NED.
- ⦿ Lip squamous cell carcinoma (i.s.) 2011 → NED.

# ONCOLOGICAL HISTORY



# ONCOLOGICAL HISTORY

March 2017

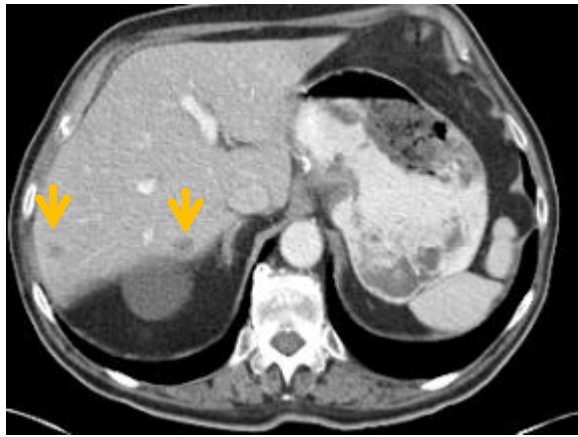
Nov 2017 – May 2019

- ⊙ After a convalescence period, a CT scan showed 2 liver metastases.
- ⊙ Included in a phase III trial with cisplatin + capecitabine +/- a PD1 inhibitor:
  - G4 asthenia + G3 hypotension in C2 → stop cisplatin (17.05.17).
  - G3 PPE in C8 → decrease the capecitabine dose (11.10.17).
  - G3 PPE in C9 → stop capecitabine (30.10.17).

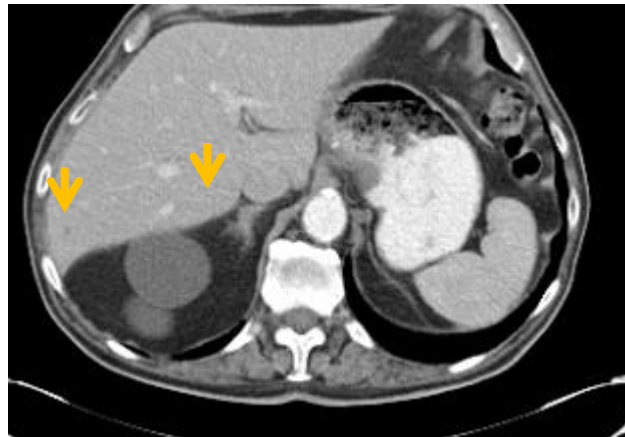
- ⊙ Since C10, he has been treated with the anti-PD1/placebo.
- ⊙ Completed 35 cycles: 08.05.19.
  - Asymptomatic, ECOG 0.

Results: The CT scan showed a progressive decrease in size of the 2 hepatic metastases with finally a complete remission of them.

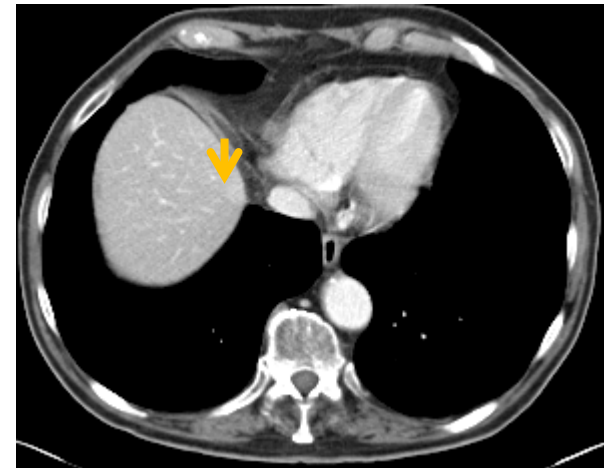
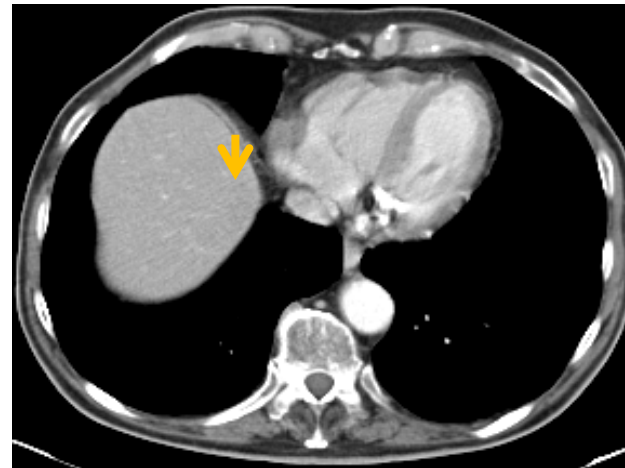
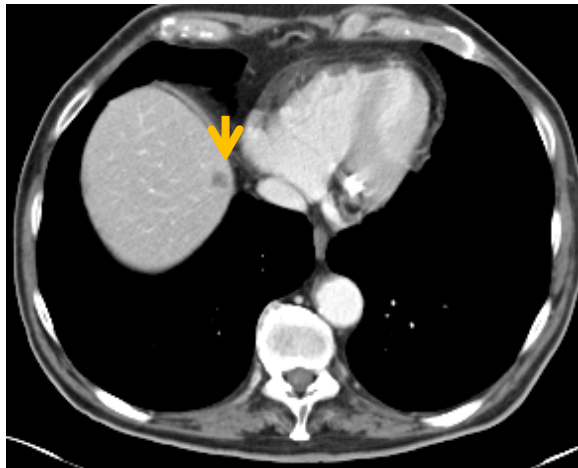
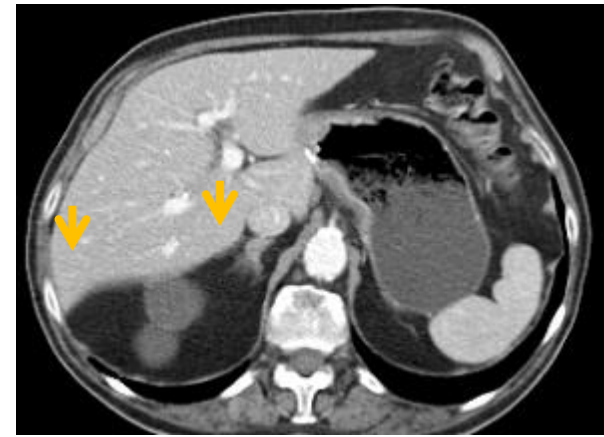March 2017



August 2017



August 2018 → June 2019



***Thanks to:***

***-Dr. Maria Alsina***

***Oncology Department Vall d'Hebron  
University Hospital***



**Thank you for your attention.**