ESMO GOOD SCIENCE BETTER MEDICINE BEST PRACTICE

HEREDITARY GASTRIC CANCER

Fátima Carneiro

i3S/Ipatimup & Medical Faculty/Centro Hospitalar São João, Porto, Portugal

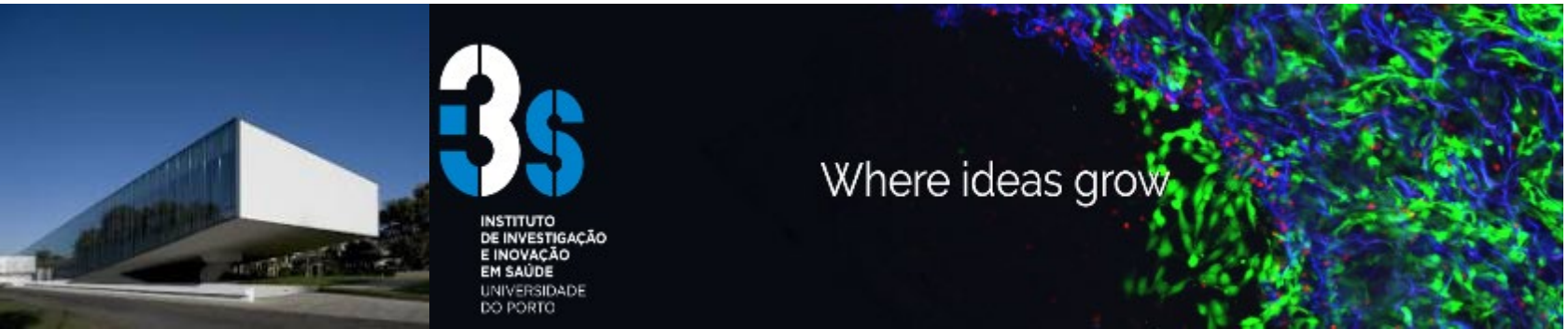

DISCLOSURE OF INTEREST

No conflicts of interest to declare

WHO CLASSIFICATION OF TUMOURS OF THE DIGESTIVE SYSTEM, 5th edition, 2019

WHO CLASSIFICATION OF TUMOURS OF THE DIGESTIVE SYSTEM, 5th edition, 2019

Genetic tumour syndromes of the digestive system

15.0: Genetic tumour syndromes of the digestive system: Introduction

15.1: Genetics

- 15.1.1: Genetic tumour syndromes of the digestive system
  - 15.1.1.3: Lynch syndrome
  - 15.1.1.4: Familial adenomatous polyposis 1
  - → 15.1.1.1: GAPPS and other fundic gland polyposes
  - 15.1.1.5: Other adenomatous polyposes
  - 15.1.1.6: Serrated polyposis
  - → 15.1.1.2: Hereditary diffuse gastric cancer
  - 15.1.1.7: Familial pancreatic cancer
  - 15.1.1.8: Juvenile polyposis syndrome
  - 15.1.1.9: Peutz-Jeghers syndrome
  - 15.1.1.10: Cowden syndrome
  - 15.1.1.11: Other genetic tumour syndromes

Contents lists available at ScienceDirect

Seminars in Diagnostic Pathology

journal homepage: www.elsevier.com/locate/semdp

Review article

Hereditary gastrointestinal carcinomas and their precursors: An algorithm for genetic testing

Clothaire P.E. Spoto[a,1], Irene Gullo[b,1], Fatima Carneiro[b], Elizabeth A. Montgomery[c], Lodewijk A.A. Brosens[a,*]

[a] Department of Pathology, University Medical Center Utrecht, Utrecht (UMCU), The Netherlands
[b] Departments of Pathology, Centro Hospitalar São João/Faculty of Medicine of Porto University and Institute for Research and Innovation in Health/Institute of Molecular Pathology and Immunology of the University of Porto (Ipatimup), Porto, Portugal
[c] Department of Pathology Johns Hopkins Hospital, Baltimore, MD, USA

Emerging Concepts in Gastric Neoplasia

Heritable Gastric Cancers and Polyposis Disorders

Rachel S. van der Post, MD[a,*],
Fátima Carneiro, MD, PhD[b,c,d,e]

FAMILIAL/HEREDITARY GASTRIC CANCER – THREE MAIN SYNDROMES –

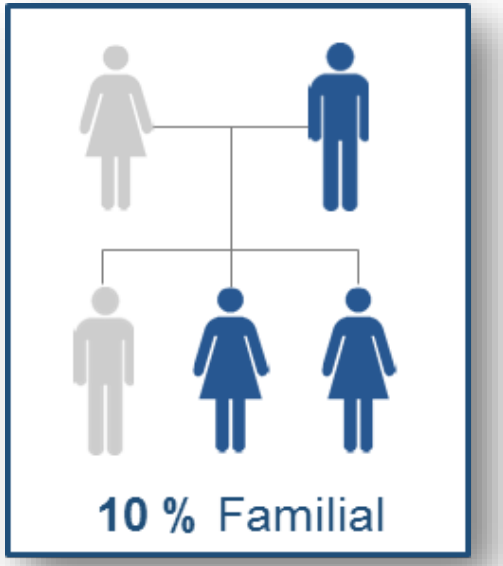

- *Hereditary Diffuse Gastric Cancer*
  HDGC - CDH1 *germline mutations mainly*
  Guilford P et al, Nat Genetics 1998
- *Gastric Adenocarcinoma and Proximal Polyposis of the Stomach*
  GAPPS - APC *promoter germline mutations*
  Worthley et al, Gut 2012
- *Familial Intestinal Gastric Cancer*
  FIGC - NO CAUSE *identified to date*
  Caldas and the IGCLC, JMG 1999 Oliveira C et al, Lancet Oncol 2015

ESMO

MAORI KINDRED

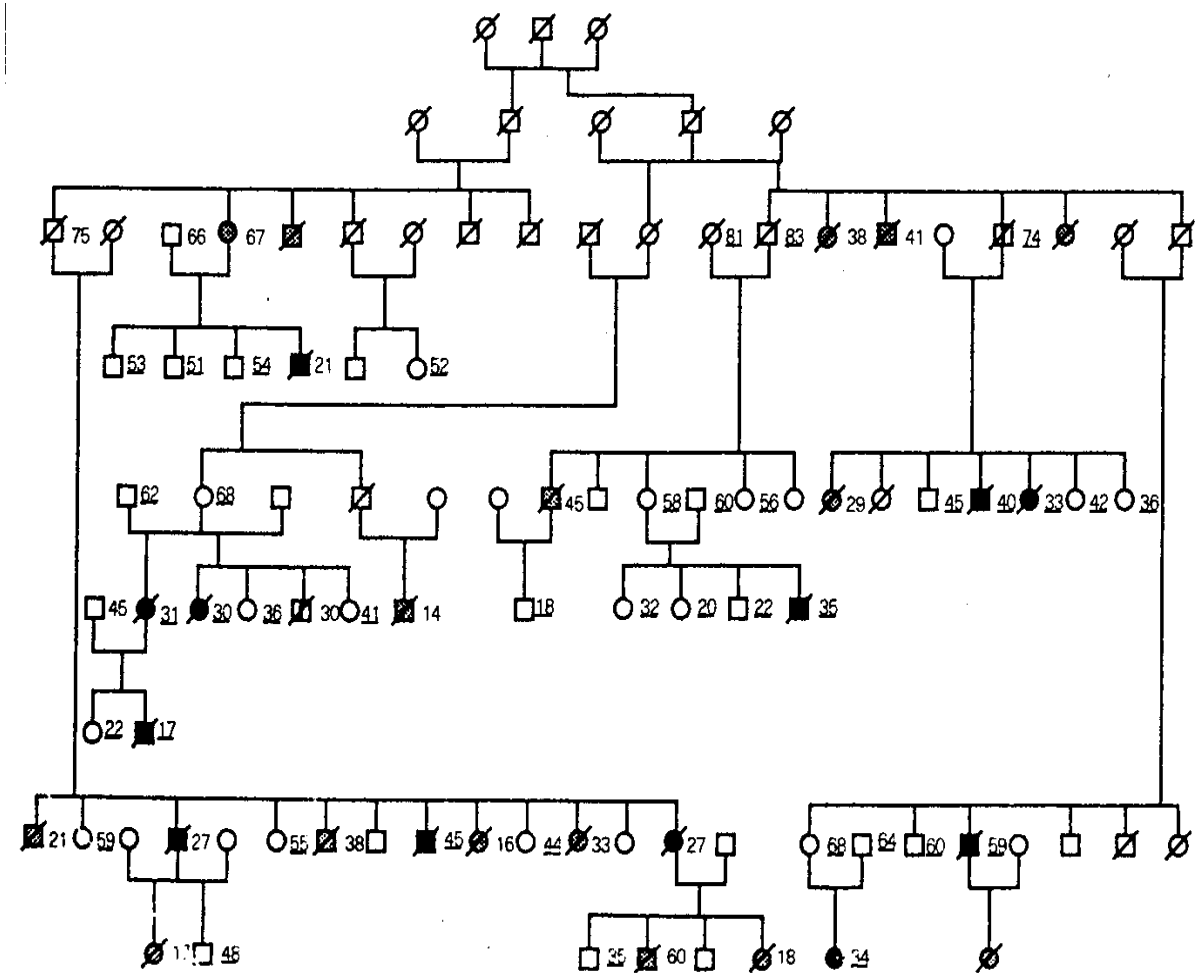

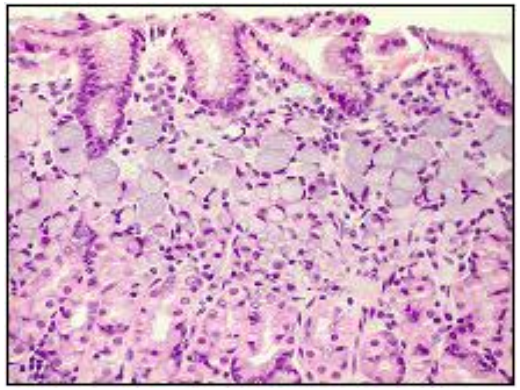

E-cadherin gene *(CDH1)* *germline mutations

Hereditary Diffuse Gastric Cancer (HDGC)

Guilford P *et al.* Nature 392:402,1998

***Gene map locus: 16q22.1 (MIM ID +192090)**

Wanaka, 2019

HEREDITARY DIFFUSE GASTRIC CANCER

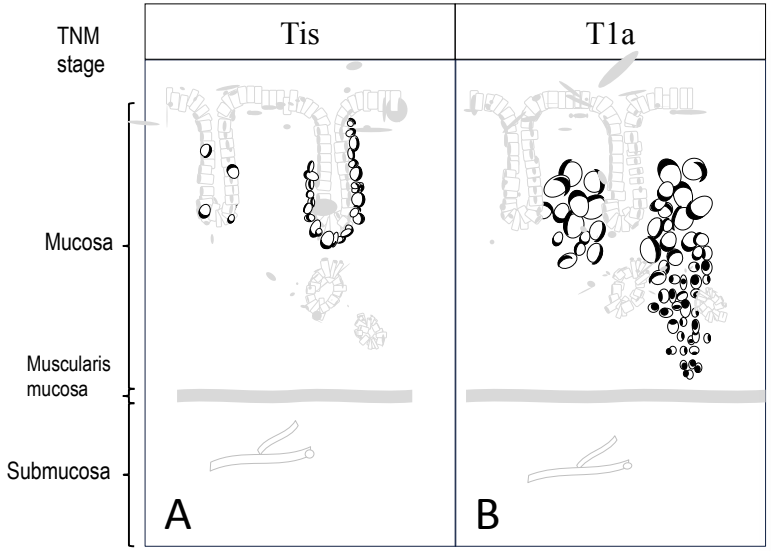

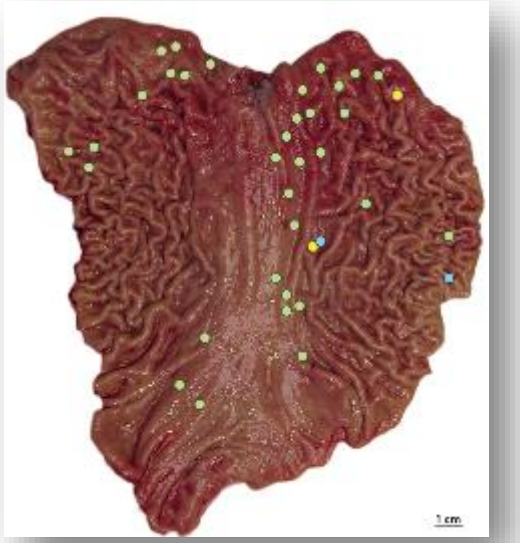

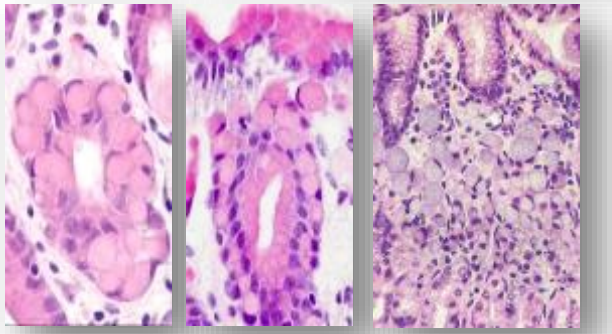

In situ carcinoma

Pagetoid spread

T1a intramucosal signet-ring cell

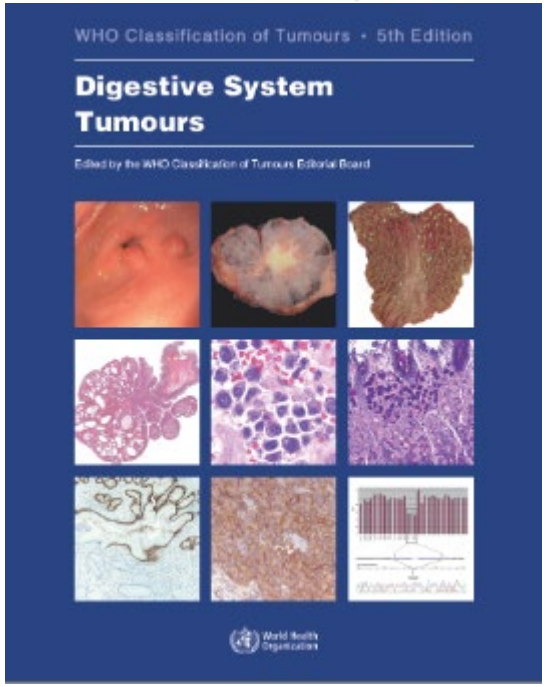

WHO – 5th Edition, 2019

GENETIC SUSCEPTIBILITY
(germline alterations)

HEREDITARY – *CDH1* germline mutations

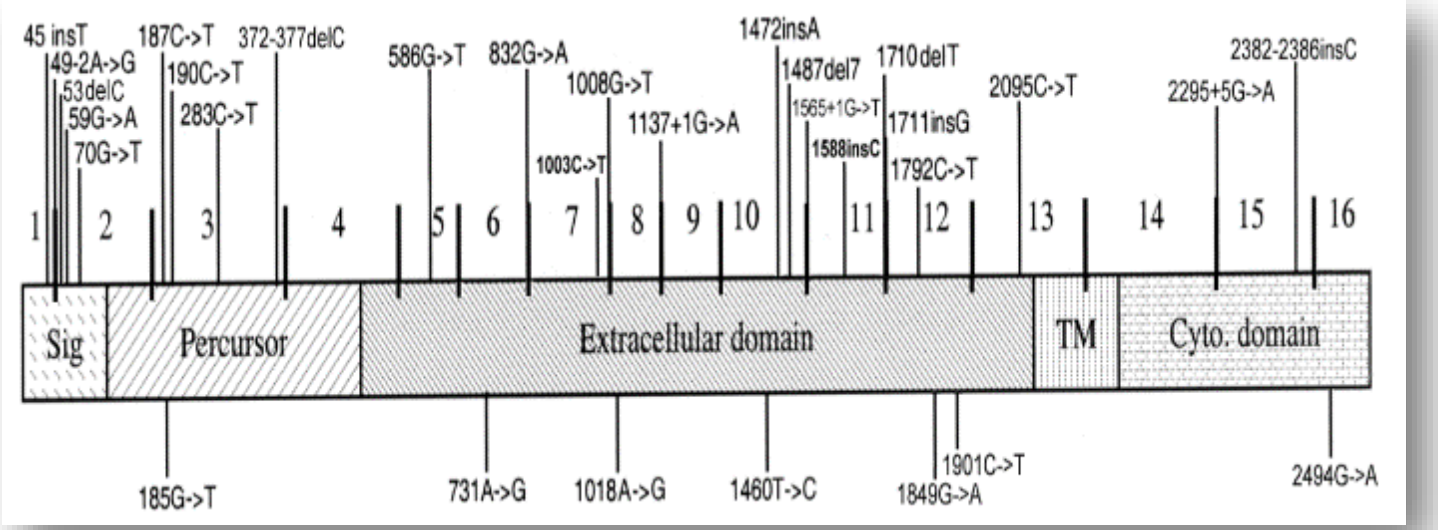

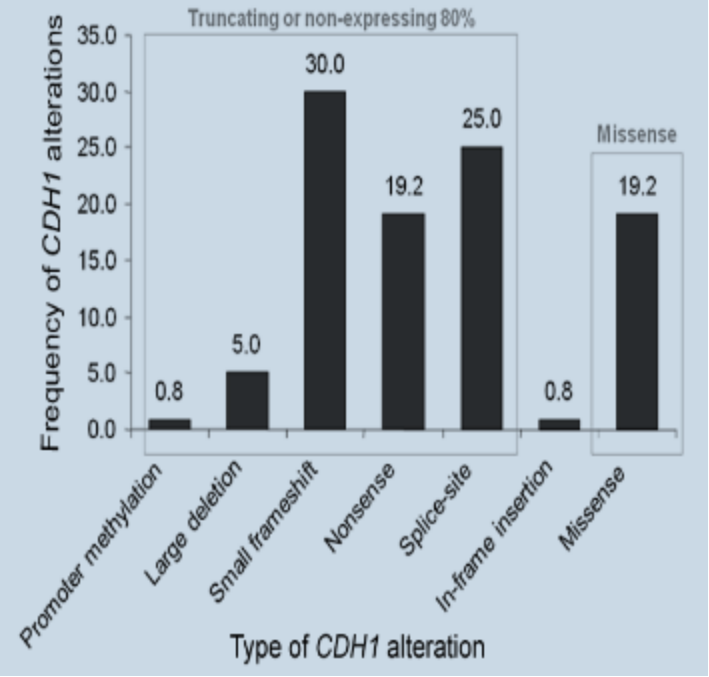

THE-CADHERIN SCHEMATIC REPRESENTATION

MAJOR DOMAINS IN RELATION TO THE 50 PILOT VARIANTS CURATED BY AN EXPERT PANEL

Clinically actionable variants (P, LP) are shown in the top; VUS, LB, and B variants are shown in the bottom. TM = transmembrane domain.

CDH1 INACTIVATION MECHANISM IN HDGC FAMILIES WITH CLINICAL UTILITY

1998/2002 → 2018

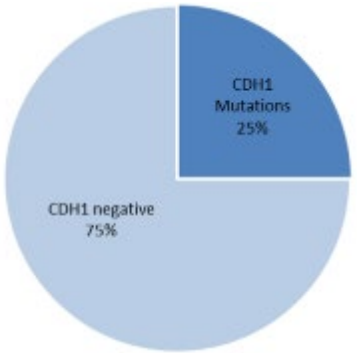

IGCLC criteria validation

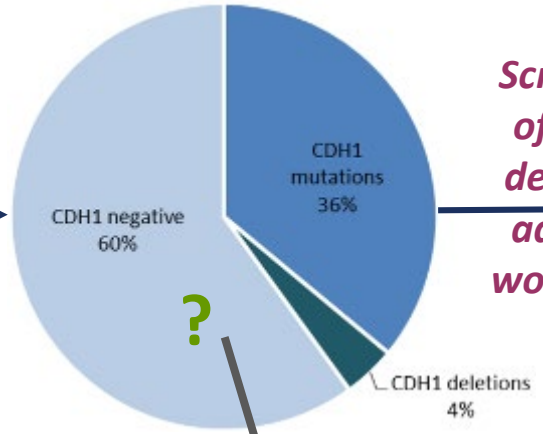

Screening of CDH1 deletions adopted worldwide

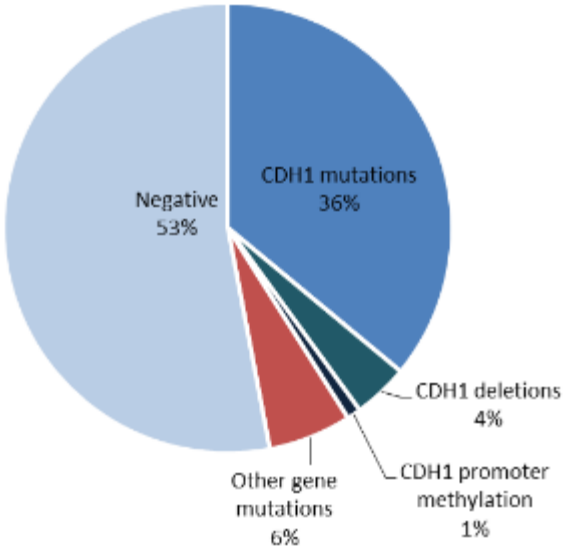

Guilford et al , Nat Genet 1998
Gayther et al, Cancer Res 1999
Oliveira et al, Hum Mutat 2002
Oliveira C et al, EJC 2004
Oliveira C et al, HMG 2009
Pinheiro H et al, HMG 2010
Pinheiro H et al, HMG 2012
Majewsky IJ et al, J Pathol 2013
Gaston D et al. PLoS Genet 2014
Hansford S et al, JAMA Oncol 2015
Vogelaar IP et al, Fam Cancer 2015
Donner I et al, Fam Cancer 2015
Oliveira et al, Lancet Oncol 2015
Vogelaar IP et al, EJHG 2017
Weren RDA et al, JMG 2018
Sahasrabudhe et al, Gastroenterology. 2017
Fewings E et al, Lancet Gastroenterol Hepatol. 2018

***Targeted DNAseq** and **Exome seq** in hundreds of probands identified few new candidate genes*

→

CTNNA1 (~10 families)
PALB2 (very rare)
TP53 (very rare)
BRCA2 (very rare)
ATM (rare; controversial)
MAP3K6 (rare; controversial)
STK11 (very, very rare)
MYD88 (very rare; controversial)

ESMO

Table 1
Characteristics of hereditary diffuse gastric cancer and familial intestinal gastric cancer

Syndrome	Gene Mutation	Mode of Inheritance	Gastric Cancer Lifetime Risk	Histology	Associated Malignancies	Important Histologic Clues	Important Clinical Clues
Hereditary diffuse gastric cancer associated with *CDH1* germline mutation	*CDH1*	Autosomal dominant	70%–80%	Diffuse	Lobular breast cancer	Mucosal foci Abnormal E-cadherin immunostaining	Familial clustering, lobular breast cancer, young age of diagnosis, cleft lip/palate
Hereditary diffuse gastric cancer associated with *CTNNA1* germline mutation	*CTNNA1*	Autosomal dominant	Unknown	Diffuse	None	Abnormal a-E-catenin immunostaining	Familial clustering and/or young age of diagnosis
Familial intestinal gastric cancer	None	Autosomal dominant	Unknown	Intestinal	None	Unknown	Familial clustering of without polyposis

van der Post RS & Carneiro F; Surg Pathol Clin. 2017

Familial gastric cancer: genetic susceptibility, pathology, and implications for management

Carla Oliveira*, Hugo Pinheiro*, Joana Figueiredo, Raquel Seruca, Fátima Carneiro

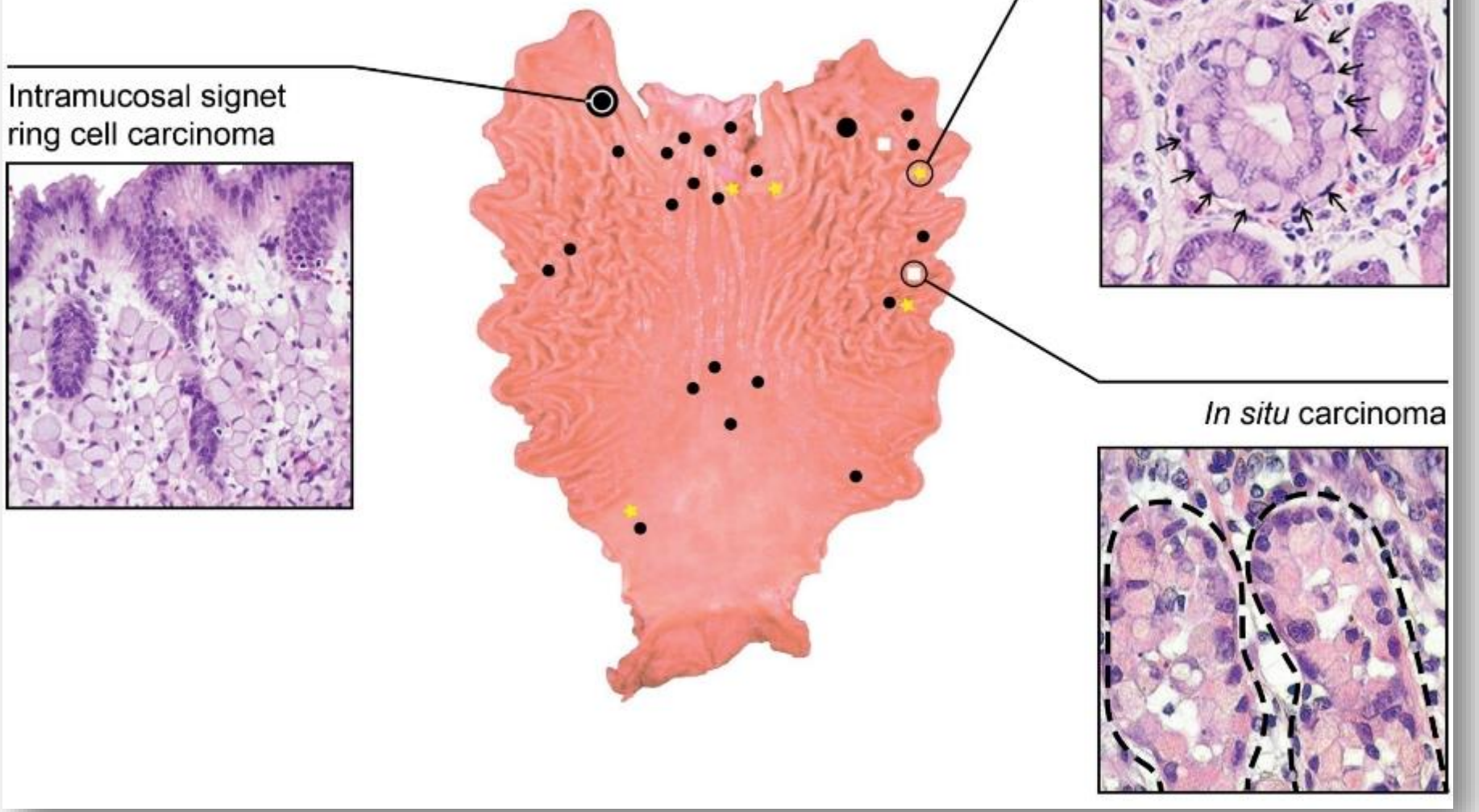

Oliveira *et al*; Lancet Oncology 16(2):e60-70, 2015

Familial gastric cancer: genetic susceptibility, pathology, and implications for management

Carla Oliveira*, Hugo Pinheiro*, Joana Figueiredo, Raquel Seruca, Fátima Carneiro

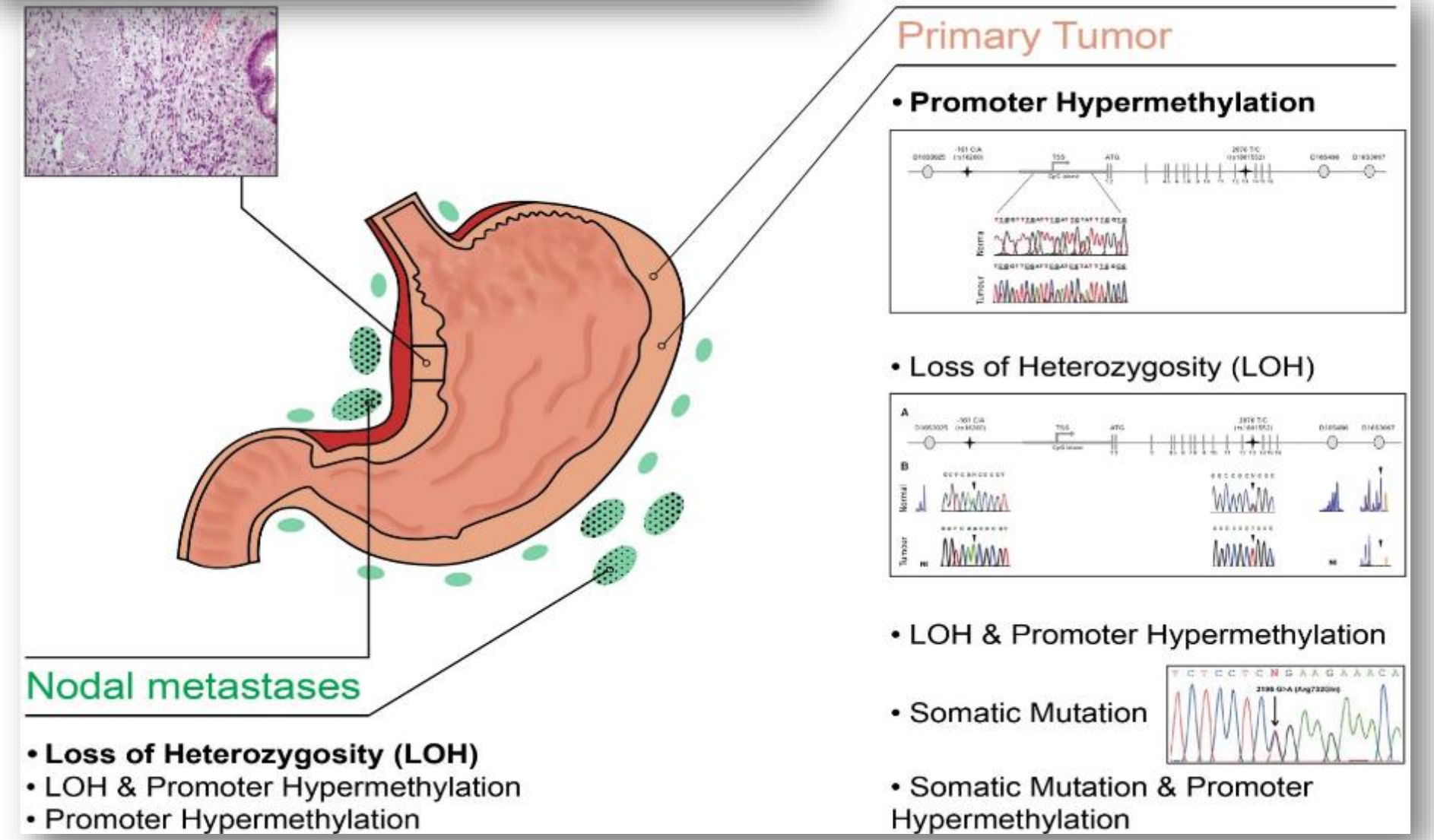

Oliveira *et al*; Lancet Oncology 16(2):e60-70, 2015

HDGC – CLINICAL MANAGEMENT AND STRATEGIES

1. Identification of patients and families at risk of developing HDGC that fulfil HDGC clinical criteria and may exhibit other HDGC-related features (CL/P or LBC)
2. Genetic testing to identify the causative germline defect
   - *CDH1* mutations/deletions
   - *CTNNA1* mutations
3. Integration in a program for risk assessment and risk reduction measures

CDH1 germline mutation carriers

Diffuse gastric cancer

1º- Risk reduction gastrectomy (indicated)

2º - Surveillance with gastroscopy and multiple biopsing (controversial)

Lobular breast cancer

1º- Bilateral surveillance from age 30 with MRI and surgery to remove early lesions (indicated)

2º - Prophylactic mastectomy (controversial)

Caldas & The IGCLC et al, J Med Genet 1999
Fitzgerald R & IGCLC, J Med Genet 2010
van der Post R & IGCLC, J Med Genet 2015

ESMO

Fam Cancer. 2019 Apr 15. doi: 10.1007/s10689-019-00127-7. [Epub ahead of print]

Hereditary gastric cancer: what's new? Update 2013-2018.

van der Post RS[1], Oliveira C[2,3,4], Guilford P[5], Carneiro F[6,7,8].

Author information

Abstract

Around 10-20% of gastric cancer patients have relatives with a diagnosis of GC and in 1-3% of patients a genetic cause can be confirmed. Histopathologically, GC is classified into intestinal-type, with glandular growth, and diffuse-type with poorly cohesive growth pattern often with signet ring cells. Familial or hereditary GC is classified into hereditary diffuse GC (HDGC), familial intestinal GC (FIGC) and polyposis forms. This review focuses on recent research findings and new concepts of hereditary GC.

KEYWORDS: E-Cadherin; Hereditary diffuse gastric cancer; Stomach

IGCLC, Wanaka 2019

ESMO

ESMO CLINICAL GUIDELINES FOR HEREDITARY GI CANCERS

Ann Oncol. 2019 Aug 5. pii: mdz233. doi: 10.1093/annonc/mdz233. [Epub ahead of print]

Hereditary gastrointestinal cancers: ESMO Clinical Practice Guidelines for diagnosis, treatment and follow-up.

Stjepanovic N[1], Moreira L[2], Carneiro F[3], Balaguer F[2], Cervantes A[4], Balmaña J[1], Martinelli E[5].

Key message: This ESMO Clinical Practice Guidelines provide updated recommendations on the management of Hereditary gastrointestinal cancers (diagnosis, treatment and follow-up).

These guidelines summarize the evidence-based data on **hereditary colorectal cancer** (CRC), **gastric cancer** (GC) and **pancreatic cancer** (PC) and provide useful clinical recommendations for identification and management of patients with hereditary gastrointestinal cancers.

FAMILIAL/HEREDITARY GASTRIC CANCER – THREE MAIN SYNDROMES –

- *Hereditary Diffuse Gastric Cancer*
  HDGC - CDH1 germline mutations mainly
  Guilford P et al, Nat Genetics 1998

- *Gastric Adenocarcinoma and Proximal Polyposis of the Stomach*
  GAPPS - APC promoter germline mutations
  Worthley et al, Gut 2012

- *Familial Intestinal Gastric Cancer*
  FIGC - No cause identified to date
  Caldas and the IGCLC, JMG 1999 *Oliveira C et al, Lancet Oncol 2015*

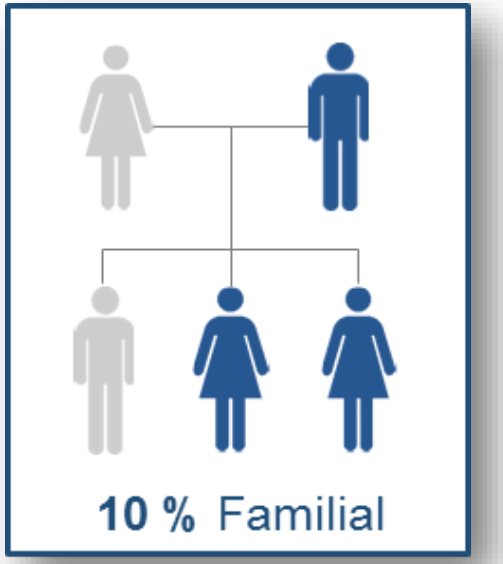

ESMO

GASTRIC ADENOCARCINOMA AND PROXIMAL POLYPOSIS OF THE STOMACH (GAPPS): A NEW AUTOSOMAL DOMINANT SYNDROME.

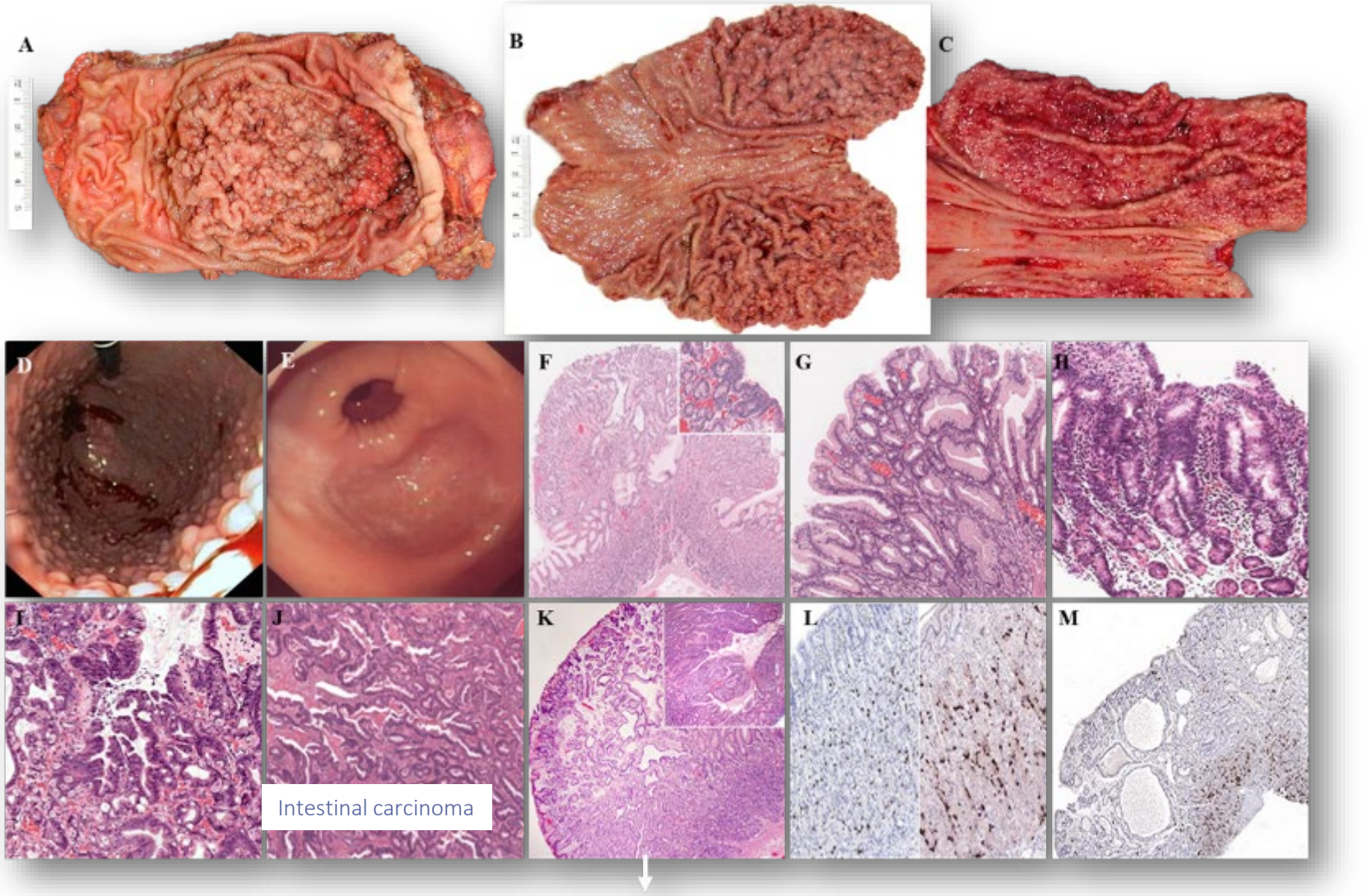

Worthley et al; Gut 61:774-779, 2012

ESMO

Gastric adenocarcinoma and proximal polyposis of the stomach (GAPPS): a new autosomal dominant syndrome

D L Worthley,[1] K D Phillips,[2] N Wayte,[3] K A Schrader,[4] S Healey,[5] P Kaurah,[4] A Shulkes,[6] F Grimpen,[7] A Clouston,[7] D Moore,[8] D Cullen,[9] D Ormonde,[9] D Mounkley,[10] X Wen,[11] N Lindor,[11] F Carneiro,[11] D G Huntsman,[4] G Chenevix-Trench,[5] G K Suthers[2,12]

ABSTRACT

Objective The purpose of this study was the clinical and pathological characterisation of a new autosomal dominant gastric polyposis syndrome, gastric adenocarcinoma and proximal polyposis of the stomach (GAPPS).

Methods Case series were examined, documenting GAPPS in three families from Australia, the USA and Canada. The affected families were identified through referral to centralised clinical genetics centres.

Results The report identifies the clinical and patholo features of this syndrome, including the predomina dysplastic fundic gland polyp histology, the exclusi involvement of the gastric body and fundus, the app inverse association with current *Helicobacter pylori* infection and the autosomal dominant mode of inheritance.

Conclusions GAPPS is a unique gastric polyposis syndrome with a significant risk of gastric adenocarcinoma. It is characterised by the autoso dominant transmission of fundic gland polyposis, including areas of dysplasia or intestinal-type gastr adenocarcinoma, restricted to the proximal stomach with no evidence of colorectal or duodenal polypo other heritable gastrointestinal cancer syndromes.

include *MUTYH*-associated polypo generalised juvenile polyposis syndro Peutz Jeghers syndrome (PJS) an syndrome.[5 6] However, FGPs are relat MAP, an autosomal recessive disorder, a PJS are often characterised by the specific hamartomatous (rather t dysplastic fundic gland) polyps.[5 6]

Sporadic FGPs are usually inno

Downloaded from gut.bmj.com on October 31, 2011 - Published by group.bmj.com

Gut Online First, published on October 25, 2011 as 10.1136/gutjnl-2011-301384

PostScript

LETTER

Familial fundic gland polyposis with gastric cancer

We read with interest the article by Worthley *et al*[1] regarding a new autosomal dominant syndrome characterised by fundic gland polyposis (FGP) and gastric cancer, which was not associated with familial adenomatous polyposis (FAP). We have experienced two similar cases of gastric adenocarcinoma occurring in pedigrees with familial FGP without FAP.

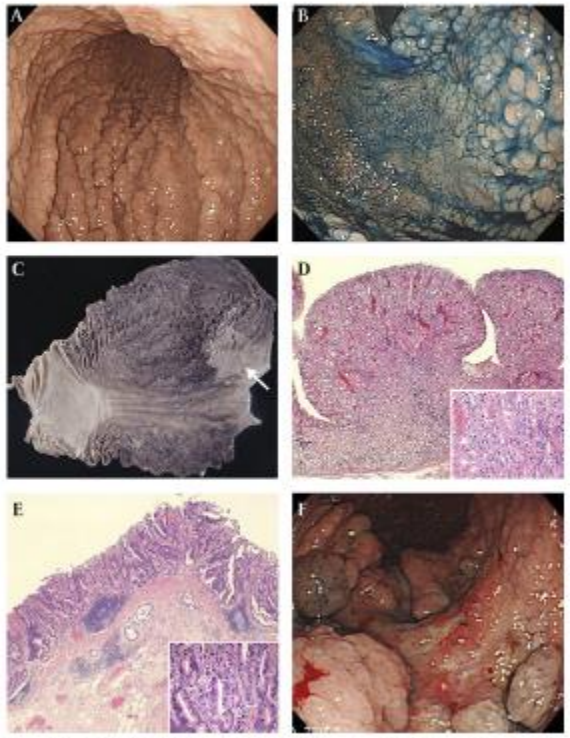

Figure 1 Endoscopic and pathological findings. (A and B) Case 1. Endoscopic images reveal numerous fundic gland polyps in the corpus (A), while a flat area circumscribed by polyps can be seen in the fundus (B). (C) Macroscopic finding of the gastrectomy specimen showing numerous

Mutations were excluded in the following genes:

- *APC*
- *MUTYH*
- *CDH1*
- *SMAD4*
- *BMPR1A*
- *STK11*
- *PTEN*

THE GENETIC DEFECT IS NOW IDENTIFIED

Point Mutations in Exon 1B of *APC* Reveal Gastric Adenocarcinoma and Proximal Polyposis of the Stomach as a Familial Adenomatous Polyposis Variant

Jun Li,[1] Susan L. Woods,[2] Sue Healey,[1] Jonathan Beesley,[1] Xiaoqing Chen,[1] Jason S. Lee,[1] Haran Sivakumaran,[1] Nicci Wayte,[1] Katia Nones,[1] Joshua J. Waterfall,[3] John Pearson,[1,4] Anne-Marie Patch,[1] Janine Senz,[5] Manuel A. Ferreira,[1] Pardeep Kaurah,[6] Robertson Mackenzie,[7] Alireza Heravi-Moussavi,[8] Samantha Hansford,[5] Tamsin R.M. Lannagan,[2] Amanda B. Spurdle,[1] Peter T. Simpson,[9,10] Leonard da Silva,[9,10] Sunil R. Lakhani,[9,10,11] Andrew D. Clouston,[12,13] Mark Bettington,[10,13,14] Florian Grimpen,[15] Rita A. Busuttil,[16,17,18] Natasha Di Costanzo,[16] Alex Boussioutas,[16,17,18,19] Marie Jeanjean,[20] George Chong,[21] Aurélie Fabre,[22,23,24] Sylviane Olschwang,[22,23,24] Geoffrey J. Faulkner,[25] Evangelos Bellos,[4,26] Lachlan Coin,[4] Kevin Rioux,[27] Oliver F. Bathe,[28,29] Xiaogang Wen,[30,31] Hilary C. Martin,[32] Deborah W. Neklason,[33] Sean R. Davis,[3] Robert L. Walker,[3] Kathleen A. Calzone,[3] Itzhak Avital,[34] Theo Heller,[35] Christopher Koh,[35] Marbin Pineda,[3] Udo Rudloff,[36] Martha Quezado,[37] Pavel N. Pichurin,[38] Peter J. Hulick,[39] Scott M. Weissman,[40] Anna Newlin,[39] Wendy S. Rubinstein,[41] Jone E. Sampson,[42] Kelly Hamman,[42] David Goldgar,[43] Nicola Poplawski,[44,45] Kerry Phillips,[44,45] Lyn Schofield,[46] Jacqueline Armstrong,[44] Cathy Kiraly-Borri,[46] Graeme K. Suthers,[45] David G. Huntsman,[7,47] William D. Foulkes,[20,48] Fatima Carneiro,[30,49] Noralane M. Lindor,[50] Stacey L. Edwards,[1] Juliet D. French,[1] Nicola Waddell,[1,4] Paul S. Meltzer,[3] Daniel L. Worthley,[2] Kasmintan A. Schrader,[6,7] and Georgia Chenevix-Trench,[1,*]

The American Journal of Human Genetics (2016),
http://dx.doi.org/10.1016/j.ajhg.2016.03.001

ESMO

APC: Genotype – Phenotype correlations

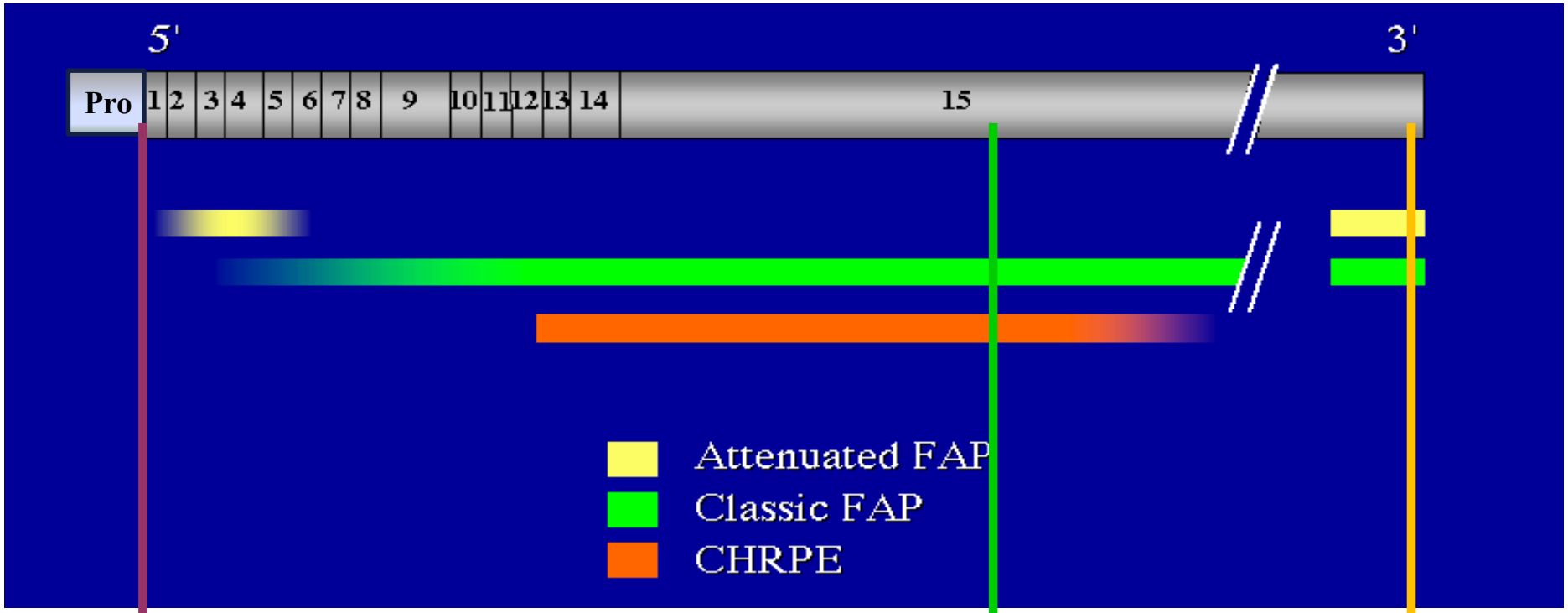

GAPPS
(the stomach is the single target)

Severe FAP
(the colon is the main target)

Attenuated FAP
(colon & stomach are the targets)

ESMO

Table 2
Characteristics of gastric polyposis syndromes

Syndrome	Gene Mutation	Mode of Inheritance	Associated Gastric Polyps	Estimates of Gastric Cancer Lifetime Risk	Histology Gastric Cancer	Important Histologic Clues	Locations of Associated Other Malignancies	Important Clinical Clues
Gastric adenocarcinoma with proximal polyposis	Point mutations in Exon 1B of *APC*	Autosomal dominant	Fundic gland polyps, few hyperplastic polyps and adenomas	Increased	Intestinal and mixed	Fundic gland polyposis with antral sparing	None	Gastric polyposis without colorectal polyposis and without use of acid-suppression therapy
Attenuated familial adenomatous polyposis	*APC*	Autosomal dominant	Predominantly fundic gland polyps, foveolar adenomas, and pyloric gland adenomas	Not increased	Intestinal	Fundic gland polyps	Colorectum, thyroid, duodenum, adrenal gland, small bowel, brain	Colorectal and duodenal polyposis

van der Post RS & Carneiro F; Surg Pathol Clin. 2017

ESMO

GAPPS (Gastric Adenocarcinoma and Proximal Polyposis of the Stomach)

ACCEPTED MANUSCRIPT

The first European family with gastric adenocarcinoma and proximal polyposis of the stomach: case report and review of the literature

Short title: First case of GAPPS in Europe

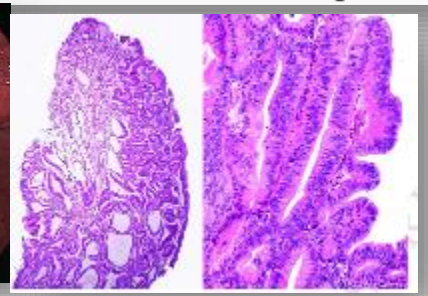

Repak R *et al*: Gastrointestinal EndoscopyDOI: 10.1016/j.gie.2016.06.023

Kasuistik

Thieme

Gastric adenocarcinoma and proximal polyposis of the stomach (GAPPS) – a rare recently described gastric polyposis syndrome – report of a case

GAPPS – eine seltene, 2012 erstmals beschriebene Magenpolypose – ein Fallbericht

Authors
Andrea Beer[1], Berthold Streubel[1], Reza Asari[2], Clemens Dejaco[3], Georg Oberhuber[1]

Foretová L, et al: **GAPPS - Gastric Adenocarcinoma and Proximal Polyposis of the Stomach Syndrome in 8 Families**
Klin Onkol. 2019 Summer;32(Supplementum2):109-117. doi: 10.14735/amko2019S109.

ESMO

Gastric Cancer
https://doi.org/10.1007/s10120-018-0855-5

CASE REPORT

First report of an Asian family with gastric adenocarcinoma and proximal polyposis of the stomach (GAPPS) revealed with the germline mutation of the *APC* exon 1B promoter region

Yasuhiro Mitsui[1] · Reiko Yokoyama[1] · Shota Fujimoto[1] · Kaizo Kagemoto[1] · Shinji Kitamura[1] · Koichi Okamoto[1] · Naoki Muguruma[1] · Yoshimi Bando[2] · Hidetaka Eguchi[3] · Yasushi Okazaki[3] · Hideyuki Ishida[4] · Tetsuji Takayama[1]

Received: 28 March 2018 / Accepted: 29 June 2018
© The International Gastric Cancer Association and The Japanese Gastric Cancer Association 2018

Fig. 2 Pedigree of the family with/without *APC* exon 1B mutation

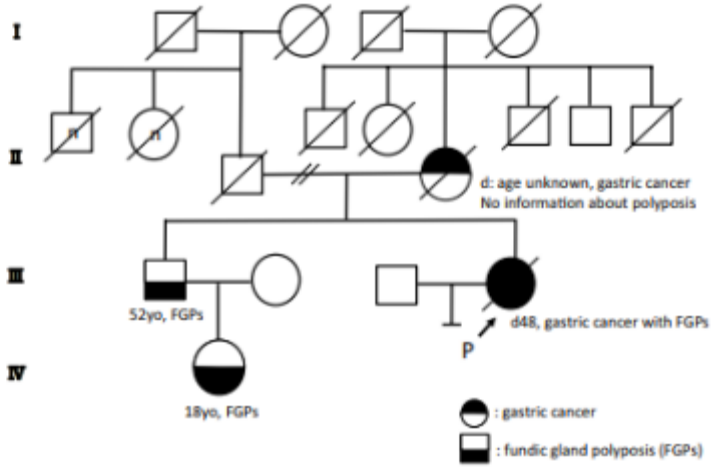

Clinical criteria	WHO 2019
Essential criteria	1. Phenotypic features: - Proximal (body and fundus) gastric polyposis with antral sparing. No evidence of colorectal or duodenal polyposis* - >100 polyps carpeting the proximal stomach in the index case or >30 polyps in a first-degree relative of another case - Predominantly fundic gland polyps (FGP) and/or fundic gland-like polyps
	2. Proband or family member with either dysplastic FGPs or gastric adenocarcinoma
	3. Mutation in the chr5: 112,043,220–12,043,224 region of promoter 1B of APC**,***
Supportive criteria **(families in whom genetic testing could be considered)**	1. Family history (autosomal dominant pattern of inheritance)
	2. Spectrum of other histological lesions: hyper-proliferative aberrant pits (HPAPs), hyperplastic polyps, gastric type adenomas

*Exclusions include other heritable gastric polyposis syndromes and use of PPIs. In patients on PPIs it is recommended to repeat the endoscopy off therapy

** The point mutations that segregate with GAPPS (c.-191T>C, c.-192A>G and c.-195A>C) are all positioned within the Ying Yang 1(YY1) binding motif of the APC gene.

*** FAP has also been caused by these mutations. Although criteria for GAPPS means there is no colorectal polyposis, testing for 1b promoter variants should still be considered for patients with FAP that are APC negative - especially if they also have FGPs.

ESMO

WHO CLASSIFICATION OF TUMOURS OF THE DIGESTIVE SYSTEM, 5th edition, 2019

Genetic tumour syndromes of the digestive system

15.0: Genetic tumour syndromes of the digestive system: Introduction

15.1: Genetics

- 15.1.1: Genetic tumour syndromes of the digestive system
  - 15.1.1.3: Lynch syndrome
  - 15.1.1.4: Familial adenomatous polyposis 1
  - 15.1.1.1: GAPPS and other fundic gland polyposes
  - 15.1.1.5: Other adenomatous polyposes
  - 15.1.1.6: Serrated polyposis
  - 15.1.1.2: Hereditary diffuse gastric cancer
  - 15.1.1.7: Familial pancreatic cancer
  - 15.1.1.8: Juvenile polyposis syndrome
  - 15.1.1.9: Peutz-Jeghers syndrome
  - 15.1.1.10: Cowden syndrome
  - 15.1.1.11: Other genetic tumour syndromes

DIAGNOSTIC ALGORITHM FOR ADENOMATOUS POLYPOSIS (FAP and Lynch syndrome Excluded)

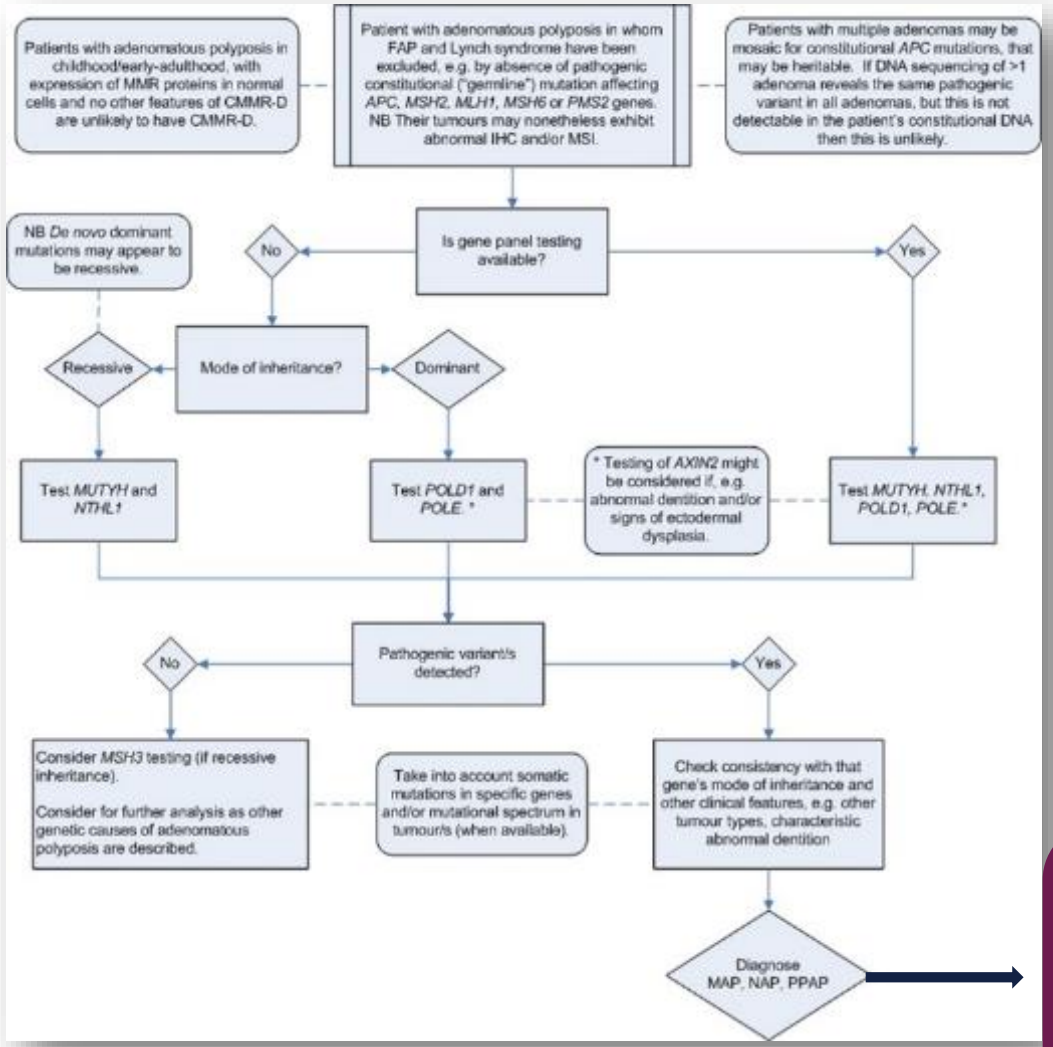

- CMMRD, constitutional mismatch repair deficiency;
- MAP, *MUTYH*-associated polyposis
- NAP, *NTHL1*-associated polyposis
- PPAP, polymerase proofreading–associated polyposis
- …

Genotype or Phenotype – What matters most in hereditary GI cancer syndromes?

⇩

BOTH

Thanks for your attention

CRITERIA FOR FAMILIAL GASTRIC CANCER

***CDH1* testing criteria in hereditary diffuse gastric cancer (HDGC updated 2015 criteria)** [1]

Full criteria

- Two or more documented cases of GC at any age in first- or second-degree relatives, with at least one confirmed DGC; or
- Personal history of DGC before the age of 40 years; or
- Personal or family history (first- or second-degree relatives) of DGC and lobular breast cancer, one diagnosed before the age of 50 years; or

Supporting criteria

- Families with bilateral or multiple cases of lobular breast cancer before the age of 50 years; or
- Families with clustering of DGC and cleft lip/cleft palate and; or
- Any patient that is diagnosed with *in situ* signet ring cells and/ or pagetoid spread of signet ring cells.

Familial intestinal-type gastric cancer (FIGC) [7]

- Two or more documented cases of intestinal gastric cancer (IGC) in first- or second-degree relatives, with at least one being diagnosed before the age of 50 years; or
- Three or more cases of IGC in first- or second-degree relatives, independent of age of diagnosis

Gastric adenocarcinoma and proximal polyposis of the stomach (GAPPS) [8, 9]

Essential criteria

1. Phenotypic features: Gastric polyps restricted to the body and fundus with antral sparing; no evidence of colorectal or duodenal polyposis; >100 polyps carpeting the proximal stomach in the index case or > 30 polyps in a first-degree relative of another case; Predominantly fundic gland (-like) polyps (exclusions include other heritable gastric polyposis syndromes and use of PPIs)
2. Proband or family member with dysplastic FGPs or gastric adenocarcinoma
3. Mutation in the chromosome 5 region of promoter 1B of *APC*

Supportive criteria

4. An autosomal dominant pattern of inheritance
5. Spectrum of other histological lesions: hyperproliferative aberrant pits (HPAPs), hyperplastic polyps, gastric type adenomas

ESMO