

EMA NETO

Centro Hospitalar Vila Nova de Gaia/Espinho, PT

Improving Palliative and Supportive care until last breath



F.L.D.A.F. | 44 years old | male
Smoker (16 pack-year)
Hepatitis C genotype 1a (cured)
Married w/ 8 years old son

Jan-2013

DIAGNOSE



**Multifocal Gastrointestinal Stromal Tumour
c-KIT mutation (exon 11), TxN1M1**

DISCLOSURE OF INTEREST

- ⦿ No conflicts of interest

Improving supportive care until last breath – Case Report

Feb-2013

1st line palliative cancer treatment → Imatinib 400mg/daily

SYMPTOMS

ECOG PS 0-1 → W: 67 Kg → Still Working

Pain (VAS 3-4): Buprenorphine patch, 35 µg/h + Morphine sulfate 10mg, SOS

Postprandial Fullness: Metoclopramide 10mg, 12/12h → **SOLVED**

Anxiety and Insomnia: Oxazepam 15mg, before sleep

1 month after starting treatment → W: 70 Kg (↑) → ECOG PS 0

Pain (↓): ↓ Buprenorphine patch 17,5 µg/h + Paracetamol SOS

Anxiety and Insomnia (Controlled): Oxazepam 15mg

Apr-2015

Progression (PET-CT: INTRABDOMINAL PROGRESSION: ↑ liver and peritoneal lesions)

2nd line palliative cancer treatment: Imatinib 800mg/daily

SYMPTOMS

ECOG PS 1 → W: 71 Kg (↑) → Still Working

Pain (↑): ↑ Buprenorphine patch, 35 µg/h + RA Morphine 10mg, SOS

Anxiety and Insomnia (controlled): Oxazepam 15mg

After Treatment adjustment → ECOG PS 0

Improving supportive care until last breath – Case Report

Mar-2016

SYMPTOMS



Progression (PET-CT: INTRABDOMINAL PROGRESSION: ↑ liver lesions)

3rd line palliative cancer treatment : Sunitinib 37,5 mg/daily

ECOG PS 0 → W: 72 Kg (↑) → Still working

Diarrhoea (G1-2): Diet and Loperamide 2 mg SOS → **SOLVED**

Pain (controlled): Buprenorphine patch, 35 µg/h + Morphine sulfate 10mg, SOS

Anxiety and Insomnia (controlled) Oxazepam 15mg

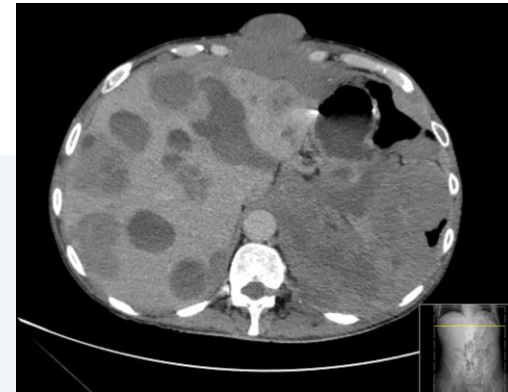

Image 1– Abdominal CT Scan:
Liver metastasis

Sep-2016

SYMPTOMS



Progression (PET-CT: INTRABDOMINAL PROGRESSION: ↑ liver and peritoneal lesions)

4th line palliative cancer treatment: Regorafenib (4weeks cycles :160mg/daily ; 3weeks on 1week off)

ECOG PS 1 → W: 73 Kg (↑) → Still working

C2-C4 → Mucositis (G1-G2): Nystatin oral suspension + topical vitamin A → **SOLVED**

C2-C16 → Palmar Plantar Erythrodysesthesia (G2)
Preventive measures + moisturizing and exfoliant cream + paracetamol SOS

> C2 → Anxiety and depressive mood (↑): Oxazepam 15mg + **Escitalopram 20mg**

> C13 → Lumbar Pain (↑): ↑ **Buprenorphine patch, 52,5 µg/h** + RA Morphine 10mg SOS

Oct-2017

After Treatment Adjustment → ECOG PS 0

Dose Reduction
(20% C6; 40% C12)

Psychological support offered
(patient refused)

Improving supportive care until last breath – Case Report

Feb-2018

Progression (PET-CT: INTRABDOMINAL PROGRESSION + PLEURAL + Meningeal invasion)

5th line palliative cancer treatment: Pazopanib 800mg/daily + Zoledronic Acid

Mar-2018 → Referred to Supportive and Palliative Care consultation

ECOG PS 1 → W: 67 Kg (↓) → Still working

Lumbar Pain (↑): ↑ Buprenorphine patch (100 µg/h → 140 µg/h → 210 µg/h)
+ Pregabalin (100mg → 200mg)
+ Sublingual Fentanyl SOS (2x 133µg → 400µg)

TC Scan → Meningeal invasion w/ medullar compression (L1) → Palliative Radiotherapy
(8Gy single fraction)

Obstipation: Oral hydration + Bisacodyl 5mg

Asthenia and Anorexia (G2) : Prednisolone 20mg + Di-hexazidine (appetite stimulant)
+ Dietary Diversification + Oral Hydration + Exercise

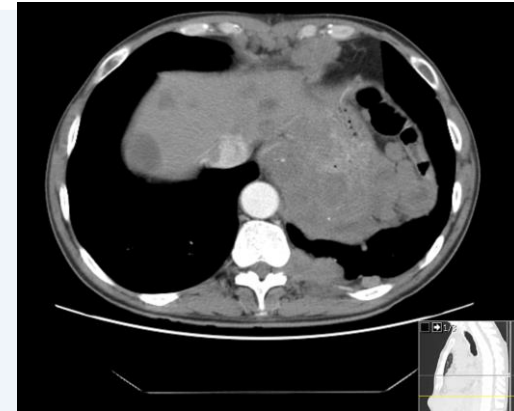


Image 2 – L1 CT Scan: meningeal metastatic involvement w/medullary compression



Always alone in consultations:
Family aware of the diagnosis but not its severity
“don’t want to alarm ”.. “young child “

Psychologic and psychiatric support
(patient refused)

Anxiety and depressive mood (controlled): Oxaxepam 15mg + Escitalopram 20mg

After Treatment Adjustment → ECOG PS 0

Improving supportive care until last breath – Case Report

May-2018

Progression (PET-CT: PLEURAL + BONE LESIONS PROGRESSION)

6th line palliative cancer treatment: Imatinib 400mg/daily + Zolendronic Acid

SYMPTOMS



ECOG PS 1-2 → W: 65 Kg (↓) → Still Working

Asthenia and Anorexia (↑): ↑ Prednisolone 40mg

Sarcopenia

+ Di-hexazidine (appetite stimulant)

+ Dietary Diversification + Oral Hydration + Exercise

Lumbar Pain (↑): ~~Buprenorphine patch 210 µg/h~~ → **Hydromorphone (80 mg)**

+ ~~Fentanyl SOS 400 µg~~ → **RA Morphine 60mg, SOS**

+ Pregabalin 200mg

After Treatment adjustment → ECOG PS 0



Family still unaware of severity of the disease

Jun -2018

Progression (PET-CT: INTRA-ABDOMINAL AND BONE LESIONS PROGRESSION)

7th line palliative cancer treatment: Imatinib 800mg/daily + Zolendronic Acid

SYMPTOMS



ECOG PS 2 → W: 62 Kg (↓) → Stop Working

Asthenia and Anorexia (↑): ~~Prednisolone 40mg~~ → **Dexamethasone 6mg**

Sarcopenia

+ Di-hexazidine (appetite stimulant)

+ Dietary Diversification + Oral Hydration + Exercise

Lumbar Pain (↑): ↑ **Hydromorphone (80 mg → 84 mg)**

+ RA Morphine 60mg, SOS

+ Pregabalin 200mg



Patient agrees to bring family to Palliative Care Consultation

Improving supportive care until last breath – Case Report

Jun -2018

1 week later → Emergency Department

SYMPTOMS



- Abdominal Pain (VAS 7)
- Fecaloid Vomit
- Fever (TT: 39°C)



**Paralytic Ileus
(w/sepsis)**



Best Supportive Care



Family still unaware of the severity of the disease
Disease and prognosis explained in the ER setting

Hospital Admission → Internal Medicine Department (w/Palliative Care team support)

Palliative Sedation to control symptoms

Morphine Perfusion (4mg/h) + Morphine 4mg iv bolus (SOS) + Midazolam

Psychiatric Support provided to Family



24 hours later → DIED AT HOSPITAL

29/06/2018

The background features a purple gradient with a central white horizontal band. Overlaid on this are various white circular and line patterns, including solid and dashed lines forming interconnected circles and arcs, creating a network-like or molecular structure.

Thank you for your attention