Endoscopic diagnosis and treatment for T1 early gastric cancer

Sho Suzuki

Division of Gastroenterology and Hepatology

Nihon University School of Medicine

NIHON UNIVERSITY

Disclosure of Conflicts of Interest

- There are no conflicts of interest to declare.
- There are no financial relationships with a commercial entity relevant to this presentation.

ESMO guideline for gastric cancer

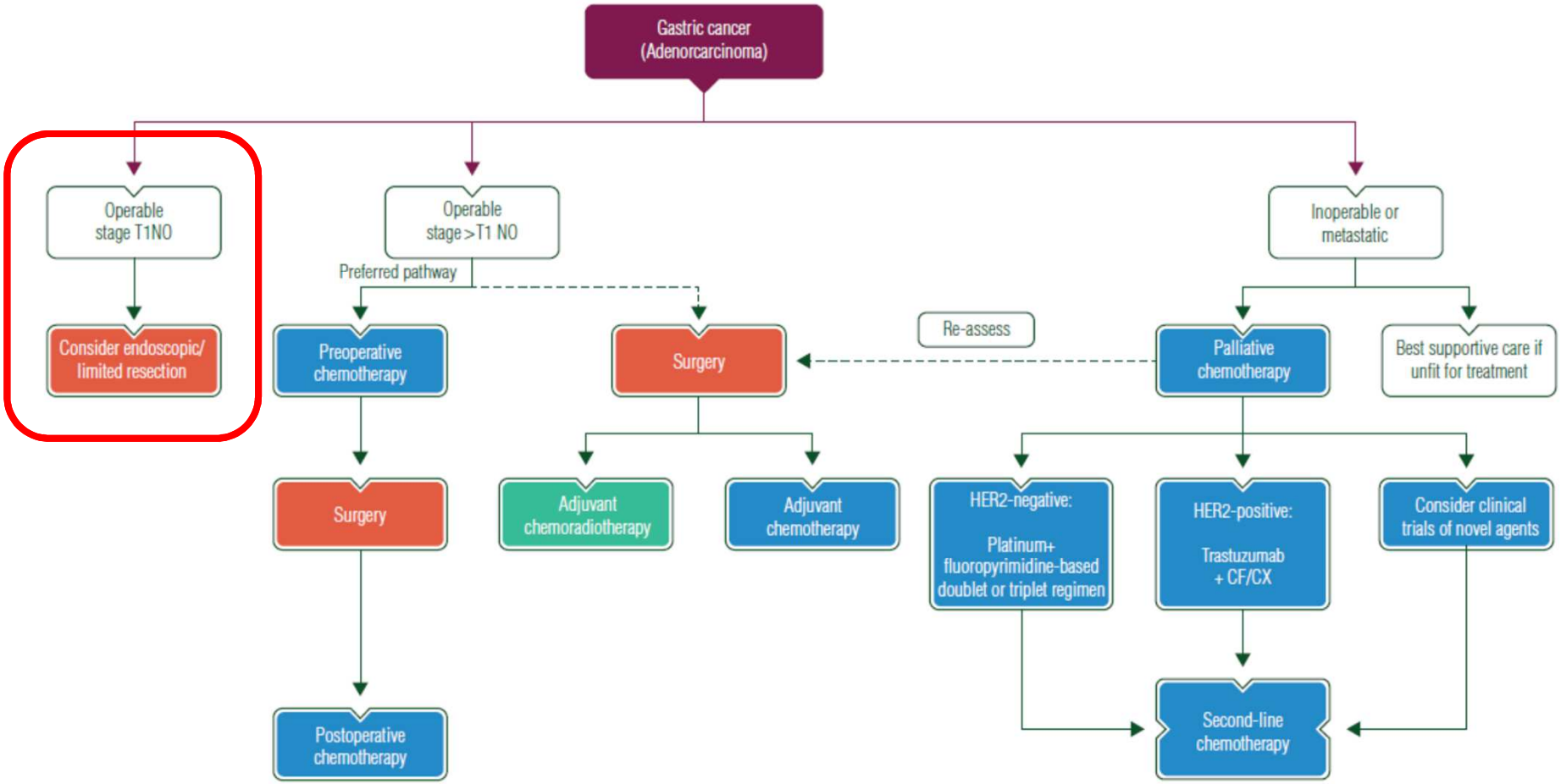

Figure 1. Gastric cancer treatment algorithm.

Management of T1 early gastric cancer

- **Screening:** risk stratification and endoscopic diagnosis
- **Treatment:** endoscopic submucosal dissection (ESD)
- **Prevention:** *H. pylori* eradication after ESD

Management of T1 early gastric cancer

- **Screening:** risk stratification and endoscopic diagnosis
- **Treatment:** endoscopic submucosal dissection (ESD)
- **Prevention:** *H. pylori* eradication after ESD

Main course of gastric carcinogenesis

Normal mucosa

↓

Active gastritis

↓

Chronic atrophic gastritis

↓

Intestinal metaplasia

↓

Gastric cancer

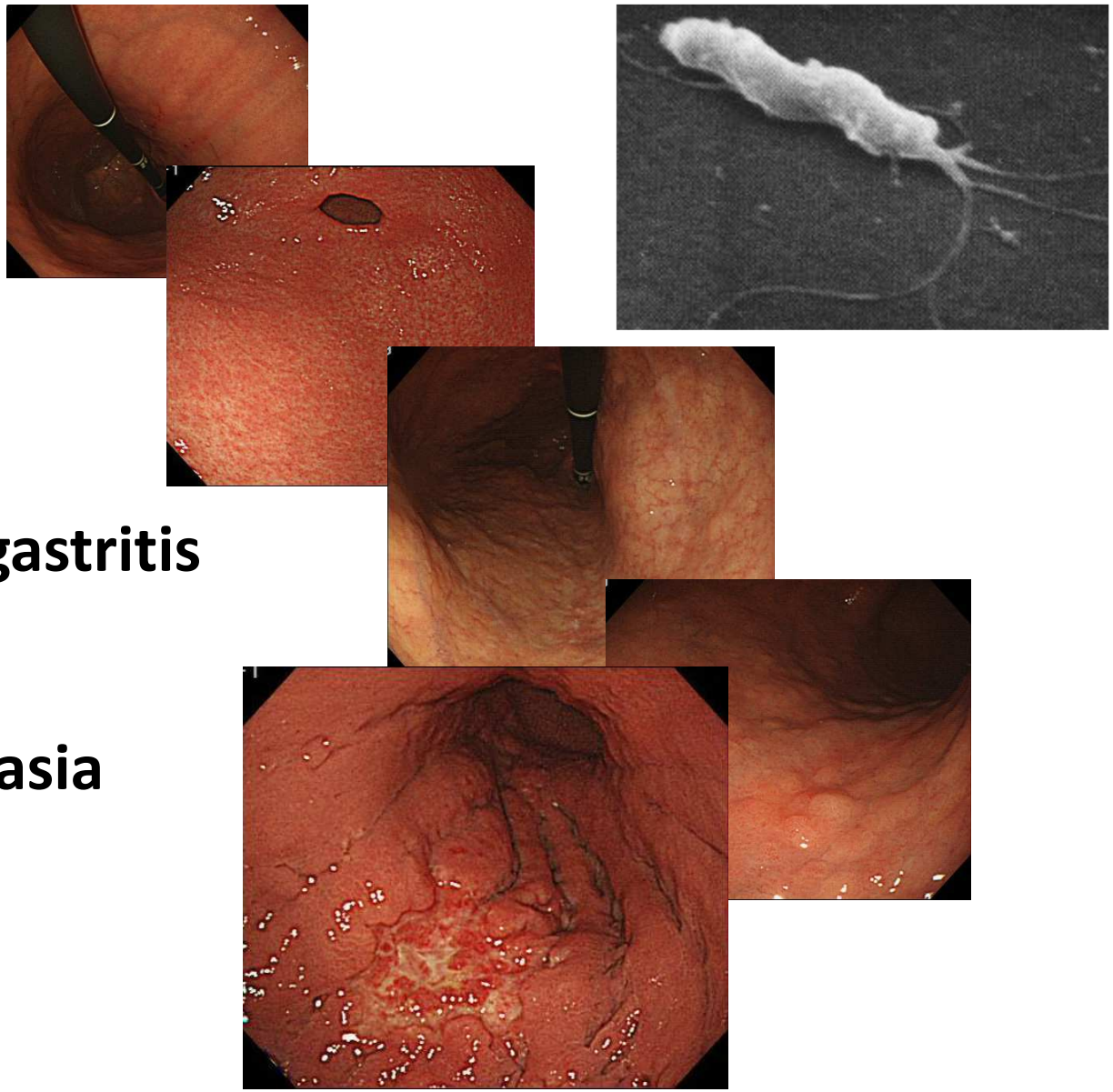

H. pylori antibody and serum pepsinogen

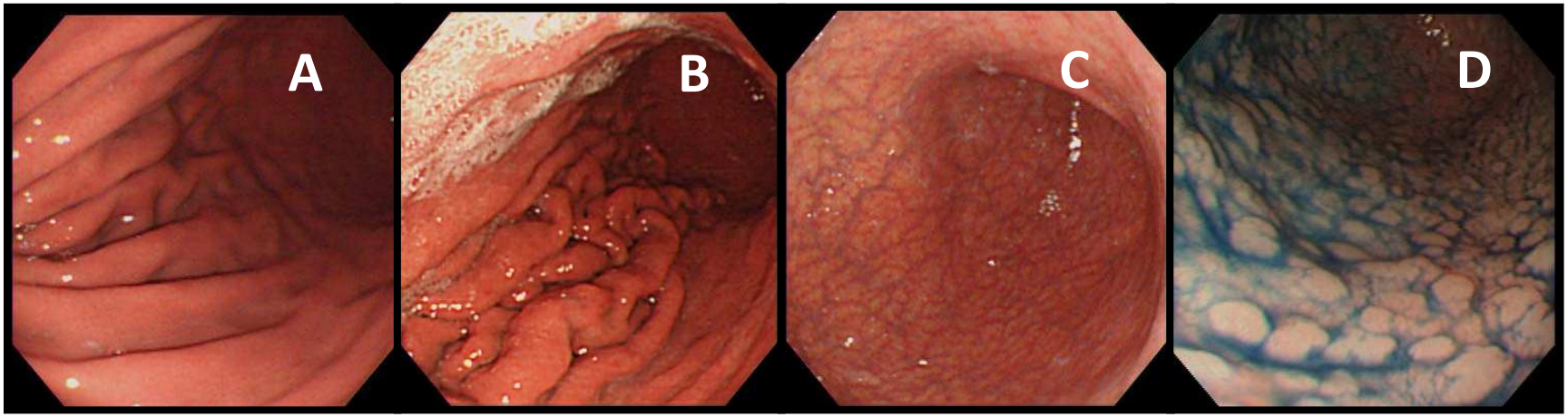

group	A	B	C	D
H. pylori antibody	−	+	+	−
Serum PG	−	−	+	+

Ohata H, et al : Int J Cancer, 2004

Number of gastric cancer & Hazard ratio

group	A	B	C	D
N	967	2341	1316	31
Average age	48.3	49.5	50.4	49.3
Follow-up (year)	7.8	7.7	7.6	7.4
N of gastric cancer	0	19	24	2
Hazard ratio	1	7.1	14.5	61.9

Ohata H, et al : Int J Cancer, 2004

Endoscopic diagnosis for EGC

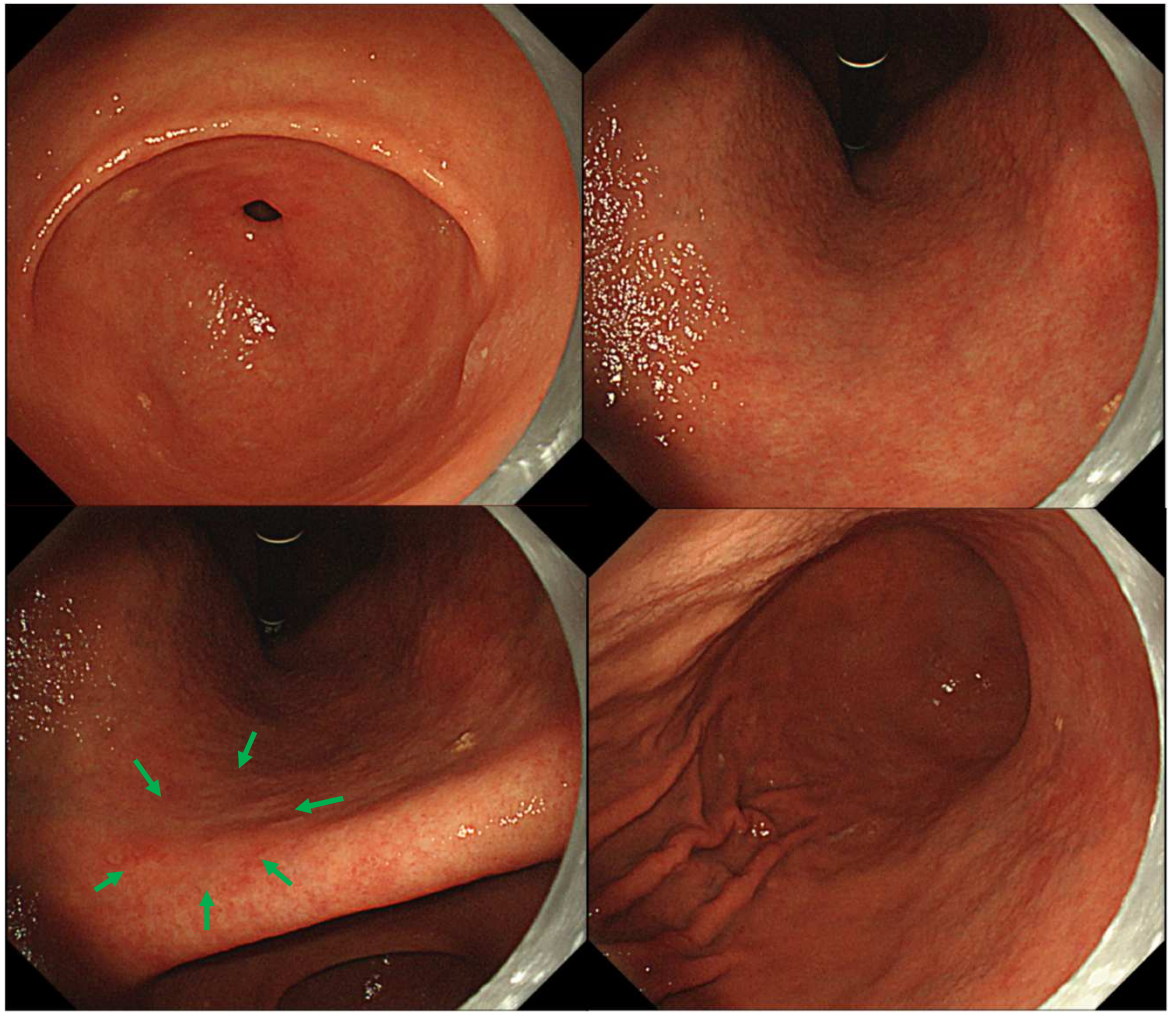

Endoscopic diagnosis for EGC

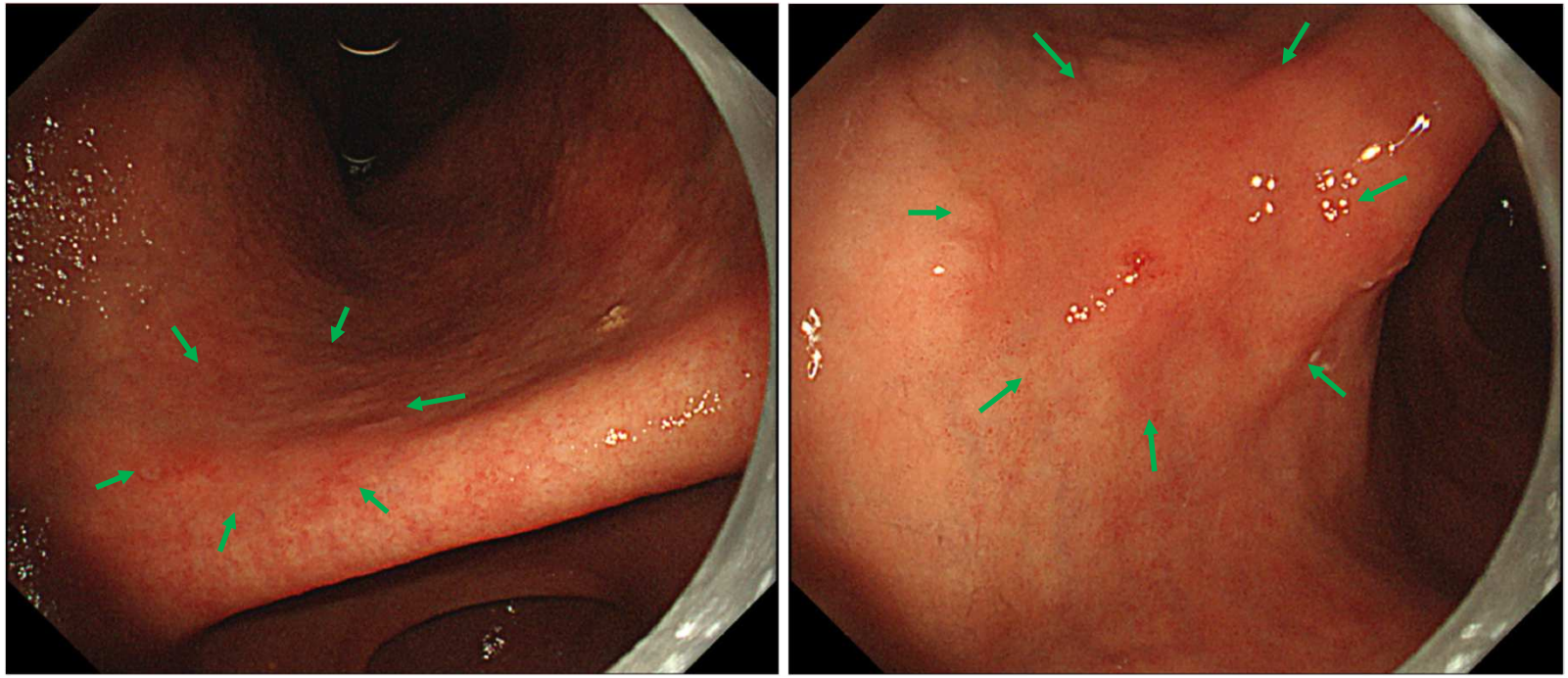

Endoscopic diagnosis for EGC

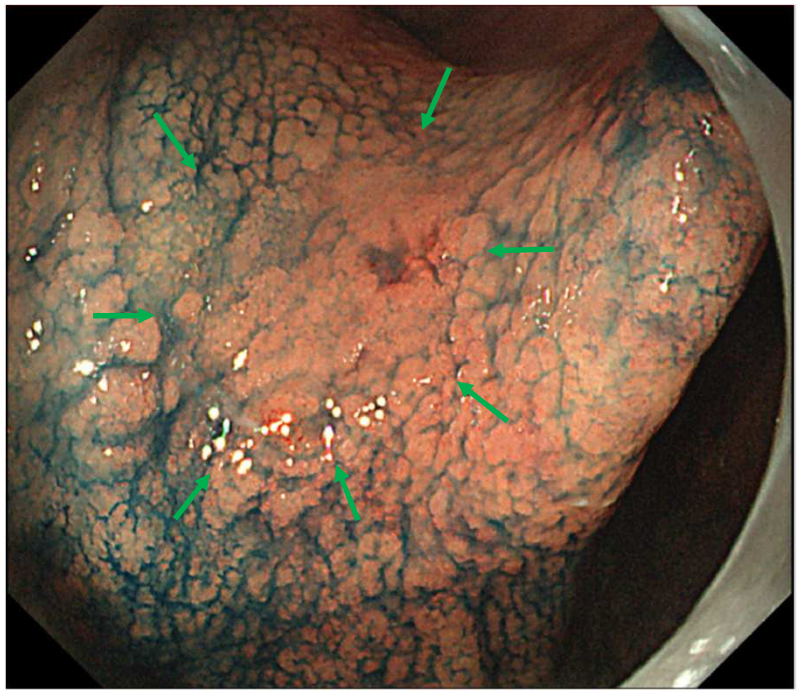

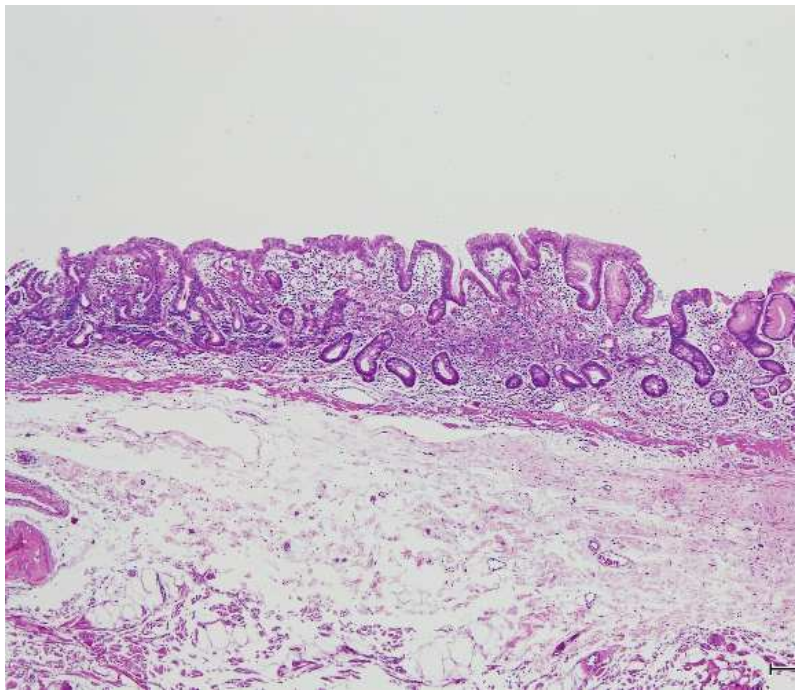

20x19mm, 0-IIb, pT1a(M), tub2, UL0, ly0, v0.

Endoscopic diagnosis need learning and experience

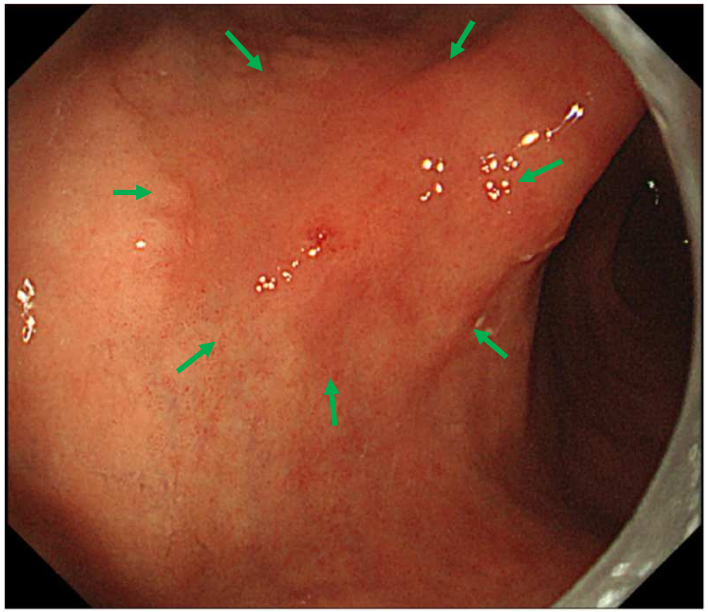

=

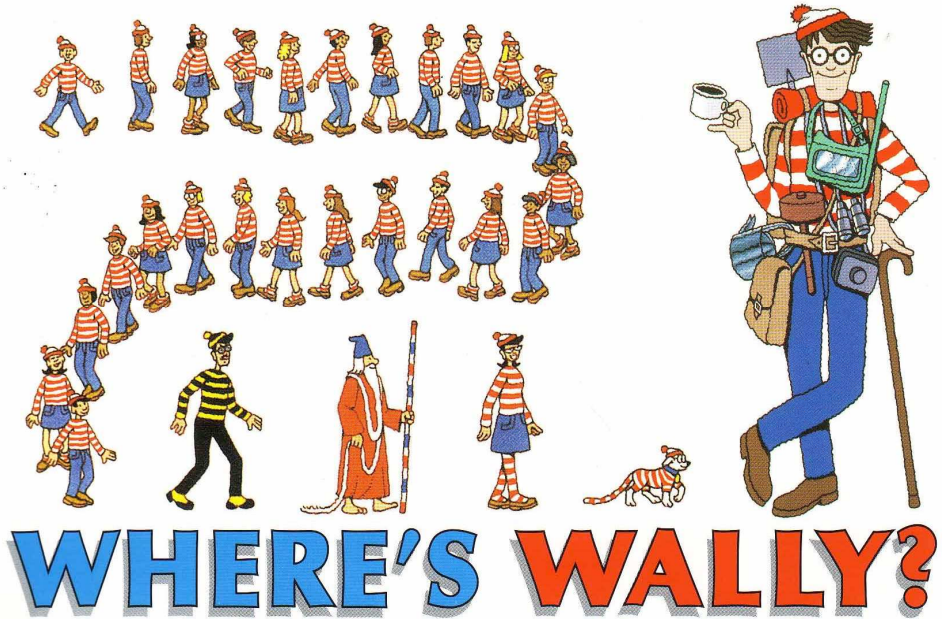

You know Wally. You can find him!





Image-enhanced endoscopy (IEE)

To augment the detection and diagnosis of lesions

- Dye-based : indigo carmine dye
  - no require special endoscopic equipment
  - cumbersome preparing dye
- Electronic-based : NBI, BLI, LCI
  - easy, time saving
  - using special endoscopic equipment

Endoscopic image of EGC using IEE

White light image

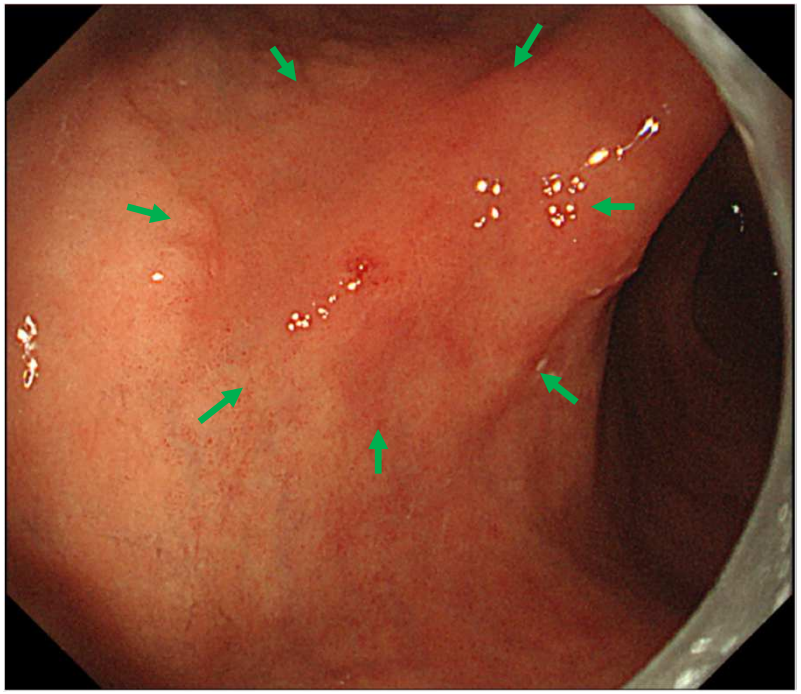

Indigo carmine dye

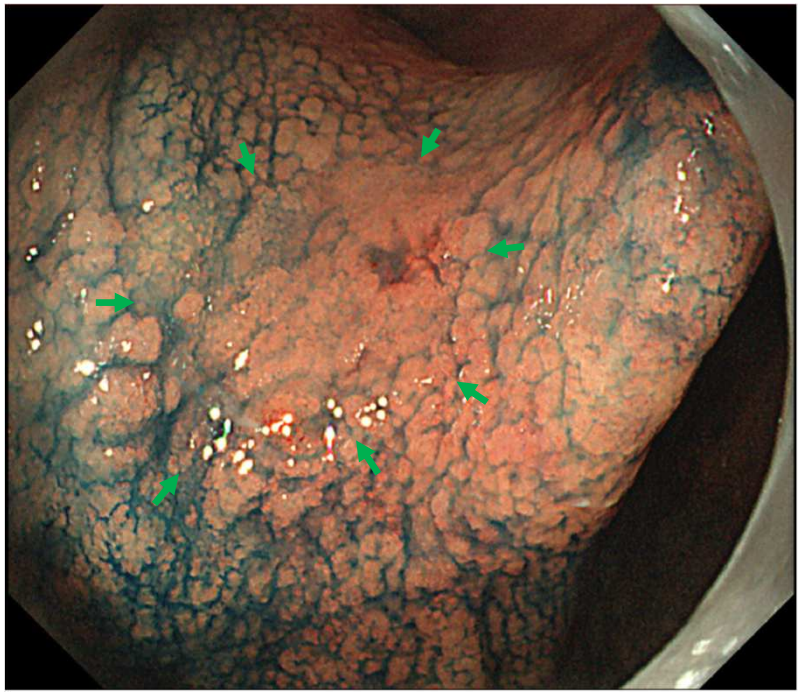

Endoscopic image of EGC using IEE

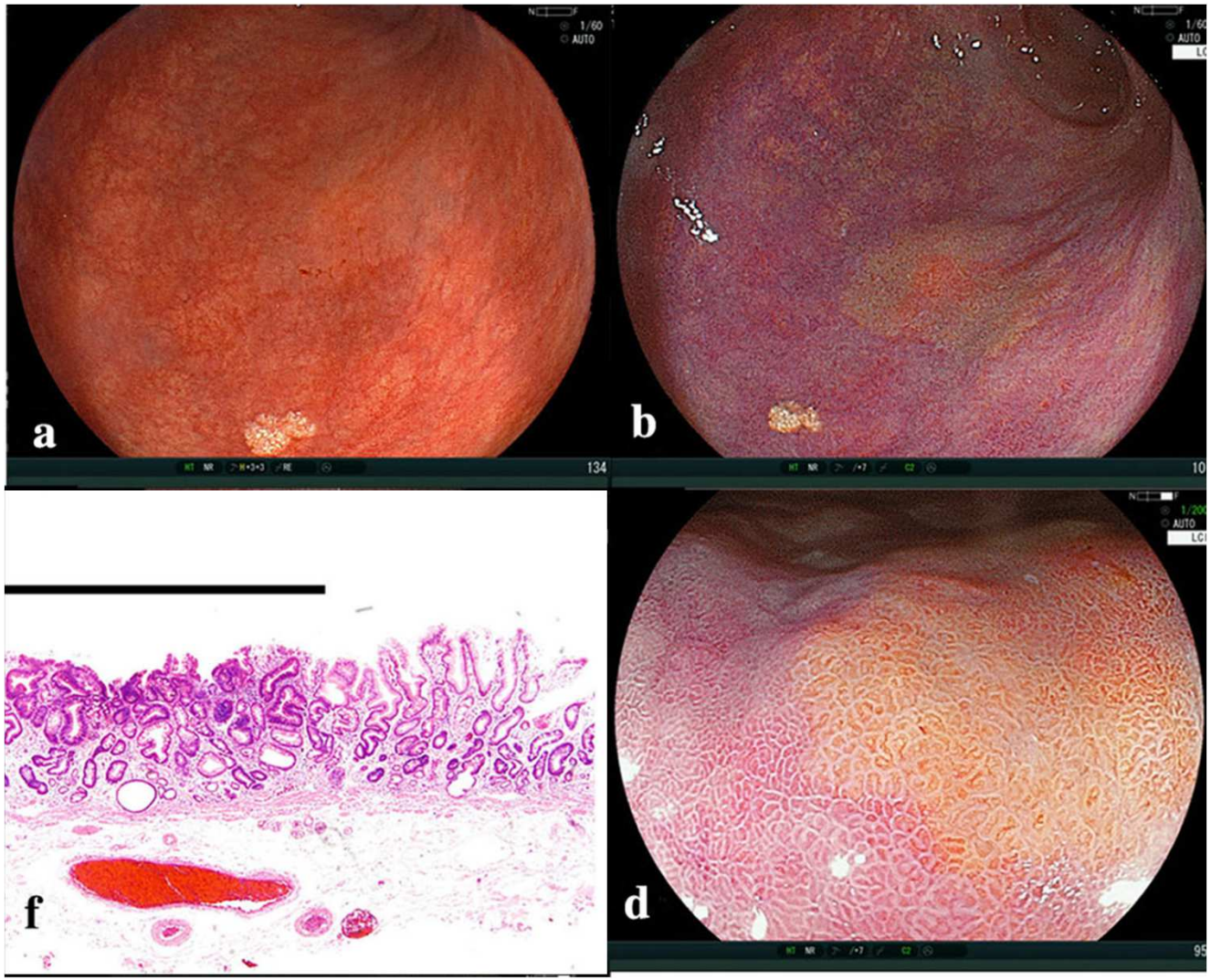

Fukuda H, et al. Clin J Gastroenterol 2015

Original article

Thieme

Linked color imaging (LCI), a novel image-enhanced endoscopy technology, emphasizes the color of early gastric cancer

OPEN ACCESS

Authors

Hiromitsu Kanzaki[1], Ryuta Takenaka[2], Yoshiro Kawahara[3], Daisuke Kawai[2], Yuka Obayashi[1], Yuki Baba[1], Hiroyuki Sakae[1], Tatsuhiro Gotoda[1], Yoshiyasu Kono[1], Ko Miura[1], Masaya Iwamuro[1], Seiji Kawano[1], Takehiro Tanaka[4], Hiroyuki Okada[1,3]

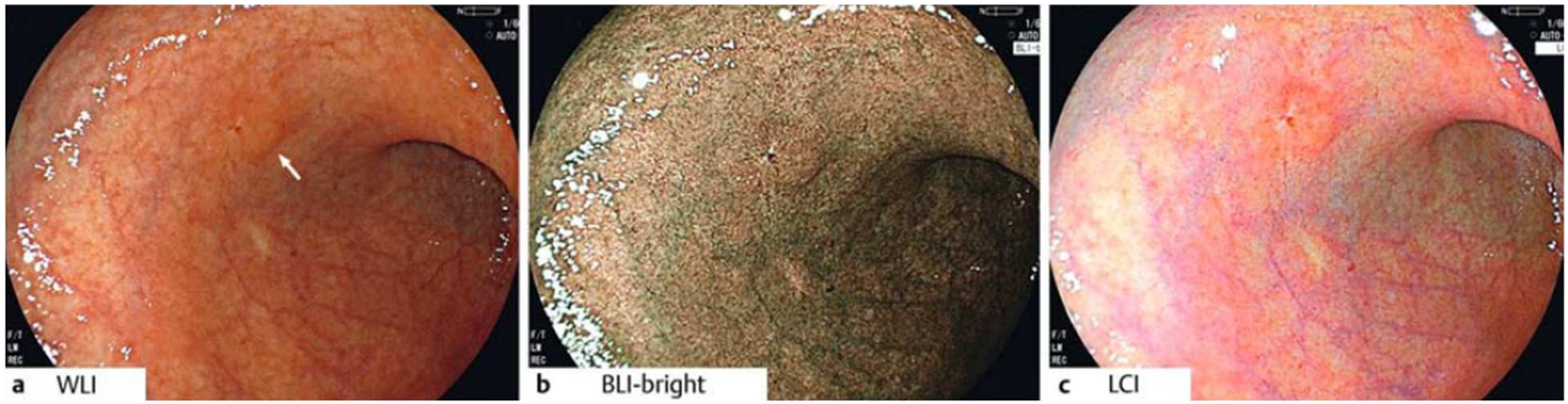

Kanzaki H, et al. Endosc Int Open 2018

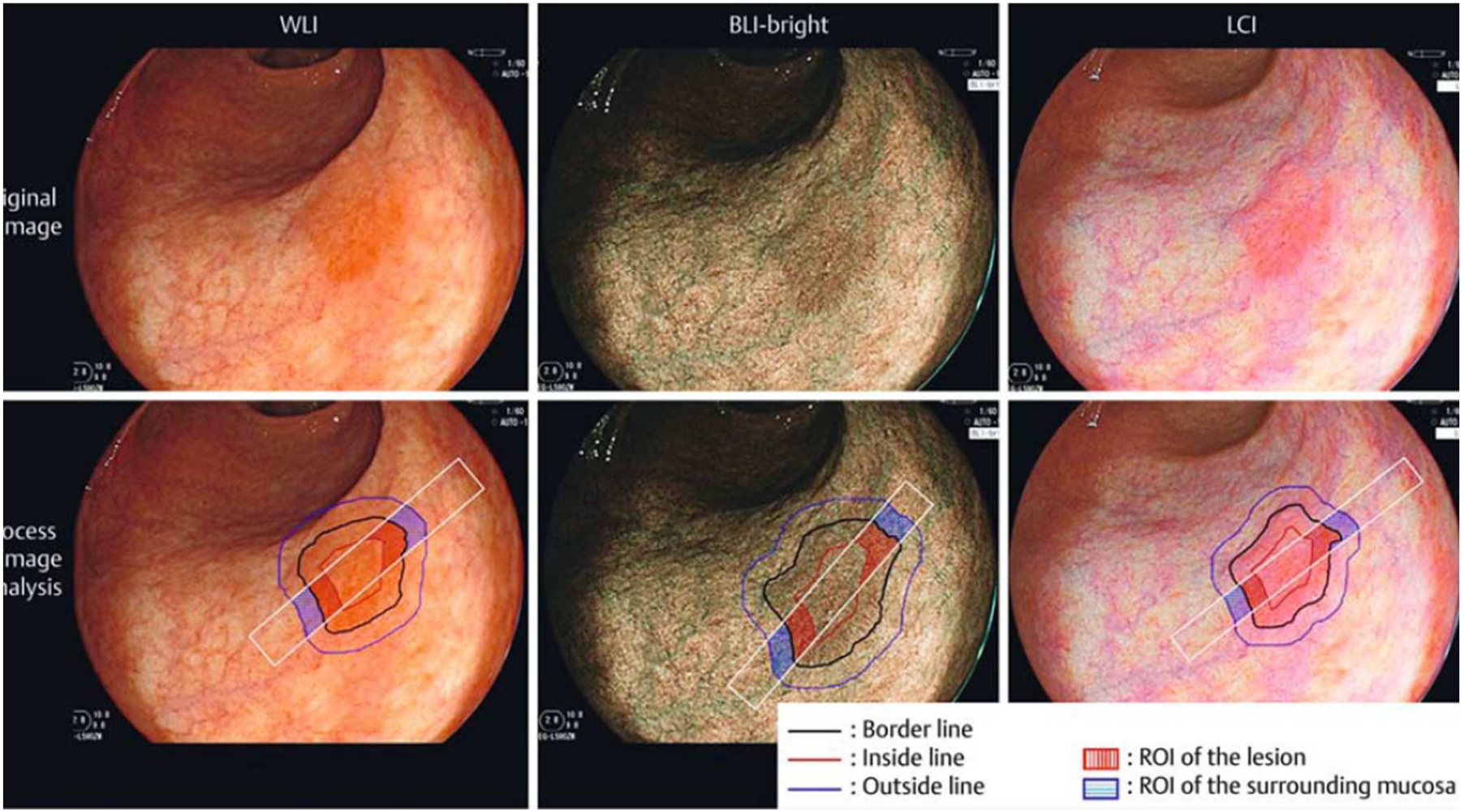

Kanzaki H, et al. Endosc Int Open 2017

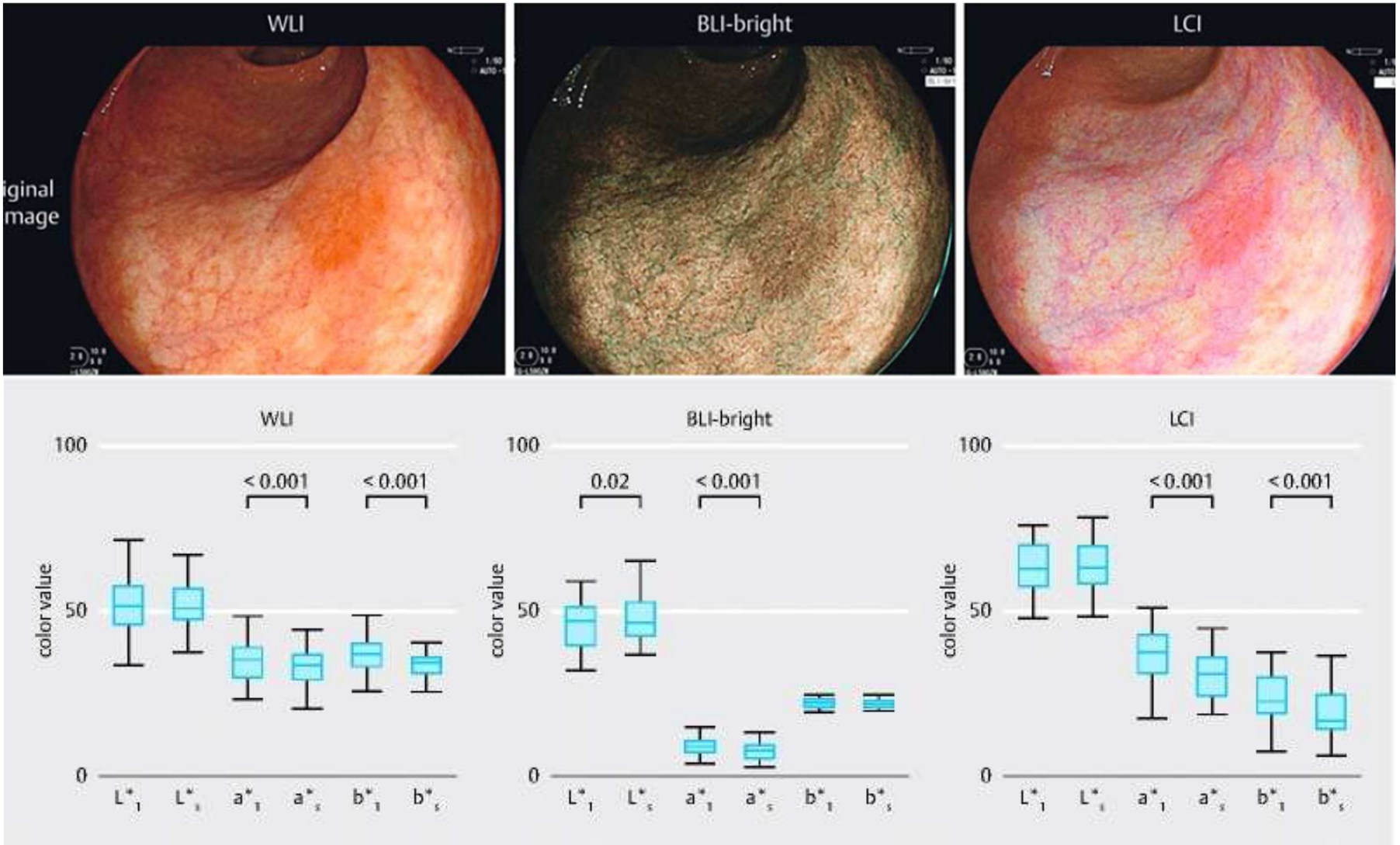

Kanzaki H, et al. Endosc Int Open 2017

AI support to detect gastric cancer?

Gastric Cancer (2018) 21:653–660
https://doi.org/10.1007/s10120-018-0793-2

ORIGINAL ARTICLE

Application of artificial intelligence using a convolutional neural network for detecting gastric cancer in endoscopic images

Toshiaki Hirasawa[1,2] · Kazuharu Aoyama[3] · Tetsuya Tanimoto[4,5] · Soichiro Ishihara[2,6] · Satoki Shichijo[7] · Tsuyoshi Ozawa[2,6] · Tatsuya Ohnishi[8] · Mitsuhiro Fujishiro[9] · Keigo Matsuo[10] · Junko Fujisaki[1] · Tomohiro Tada[2,3,11]

Hirasawa T, et al. Gastric Cancer 2018

Image recognition using AI

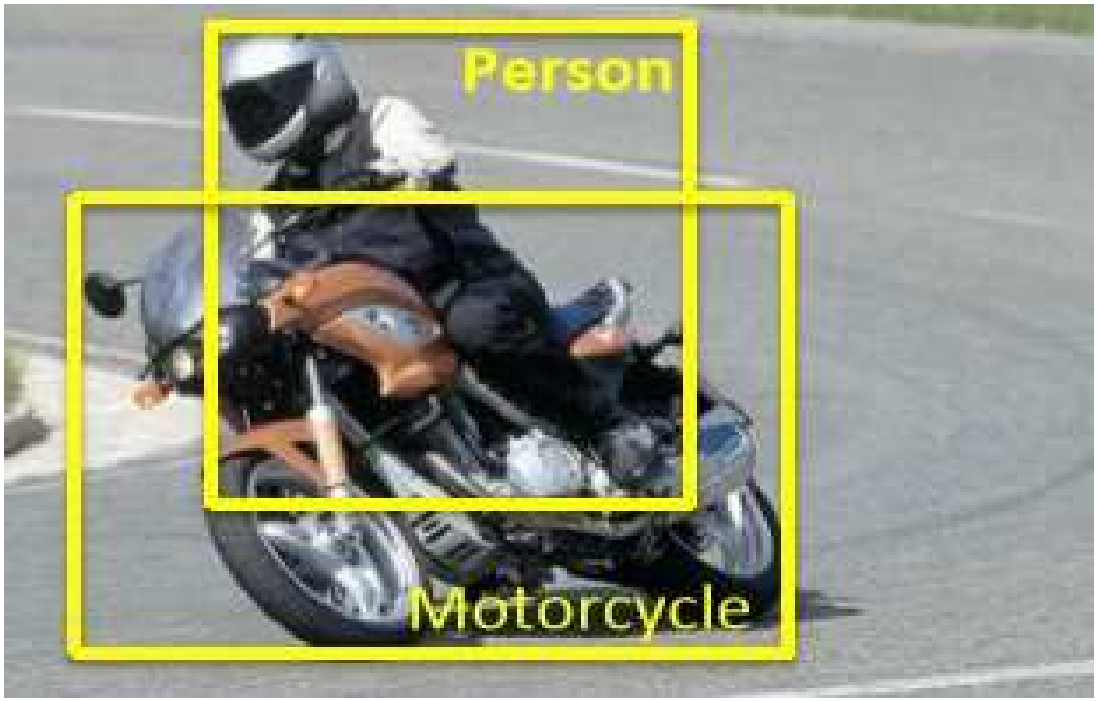

http://www.image-net.org/challenges/LSVRC/2013/slides/ILSVRC2013_12_7_13_clsloc.pdf

- Image recognition using AI with deep learning has dramatically progressed

Hirasawa T, et al. Gastric Cancer 2018

AI-based diagnostic system for gastric cancer

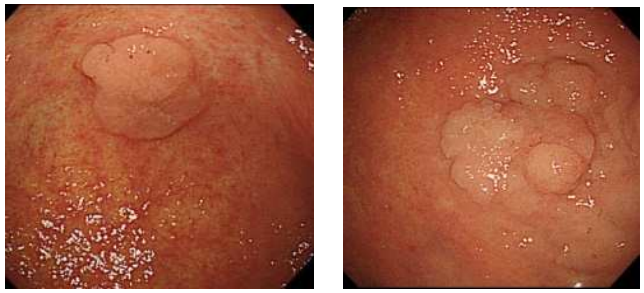

13,584 images

Machine Learning

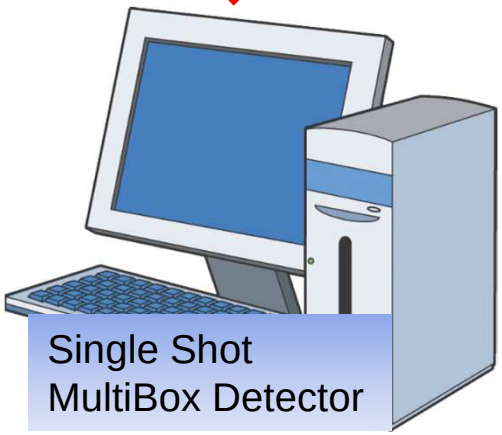

- AI system automatically extracts features of gastric cancer and learns about gastric cancer.

Hirasawa T, et al. Gastric Cancer 2018

AI-based diagnostic system for gastric cancer

Output of AI system

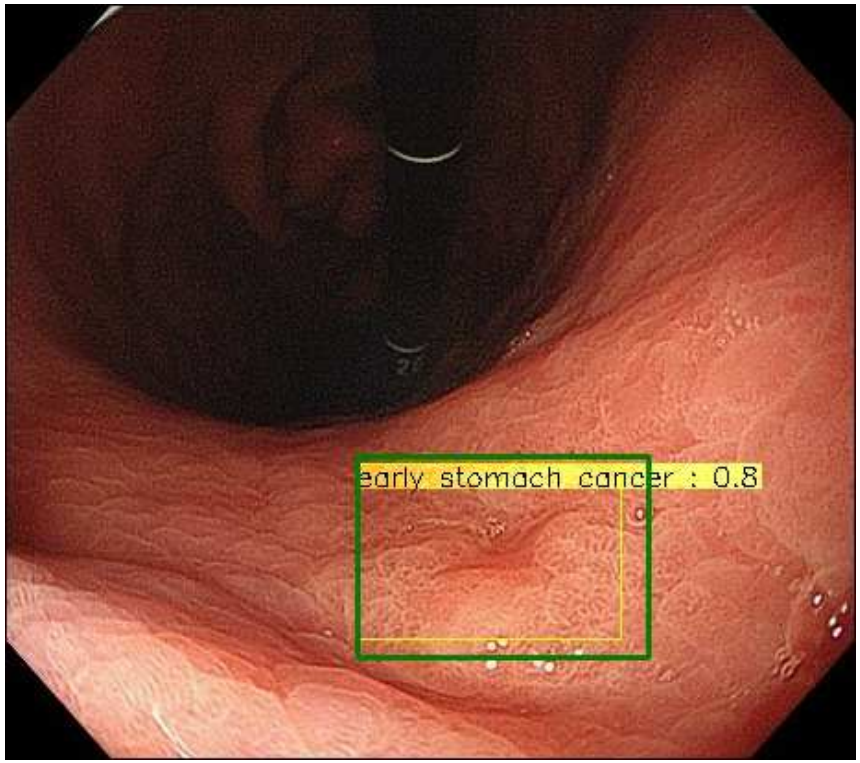

- An endoscopist manually marked
- AI system marked

Hirasawa T, et al. Gastric Cancer 2018

Accuracy of AI-based diagnostic system

Depth of tumor	Tumor size (mm)			
	≤ 5	6–10	11–20	≥ 21
T1a (mucosa)	1/6 (16.7)	11/11(100)	16/17 (94.1)	9/9 (100)
T1b (submucosa)	0/0	0/0	1/1(100)	8/8 (100)
T2 (muscularis propria)	0/0	0/0	0/0	7/7 (100)
T3 (subserosa)	0/0	0/0	0/0	2/2 (100)
T4a (serosa)	0/0	0/0	0/0	16/16 (100)

- Overall sensitivity of 92.2%
- PPV of 30.6%

Hirasawa T, et al. Gastric Cancer 2018

Management of T1 early gastric cancer

- **Screening:** risk stratification and endoscopic diagnosis
- **Treatment:** endoscopic submucosal dissection (ESD)
- **Prevention:** *H. pylori* eradication after ESD

Treatment options for T1 early gastric cancer

ESD

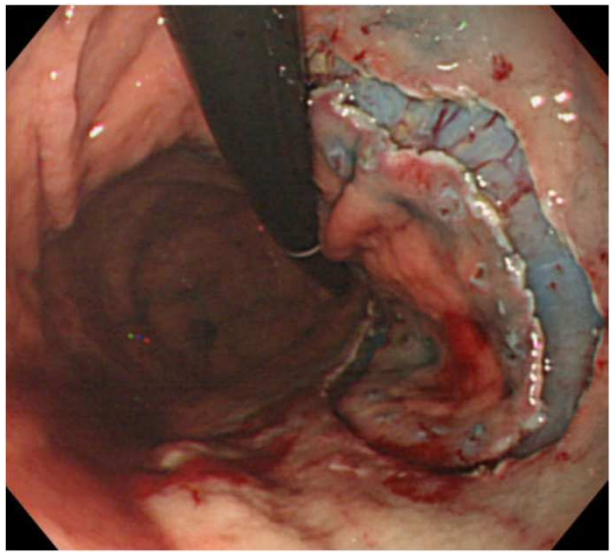

Surgery

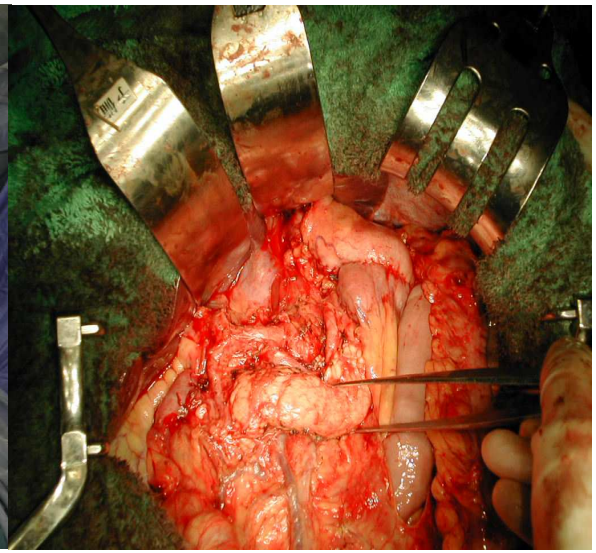

- **Curability**
- **Feasibility**

Endoscopic Submucosal Dissection (ESD)

- Marking
- Injection
- Pre-incision
  Mucosal cutting
- Submucosal dissection
- Endoscopic managements
  for complications

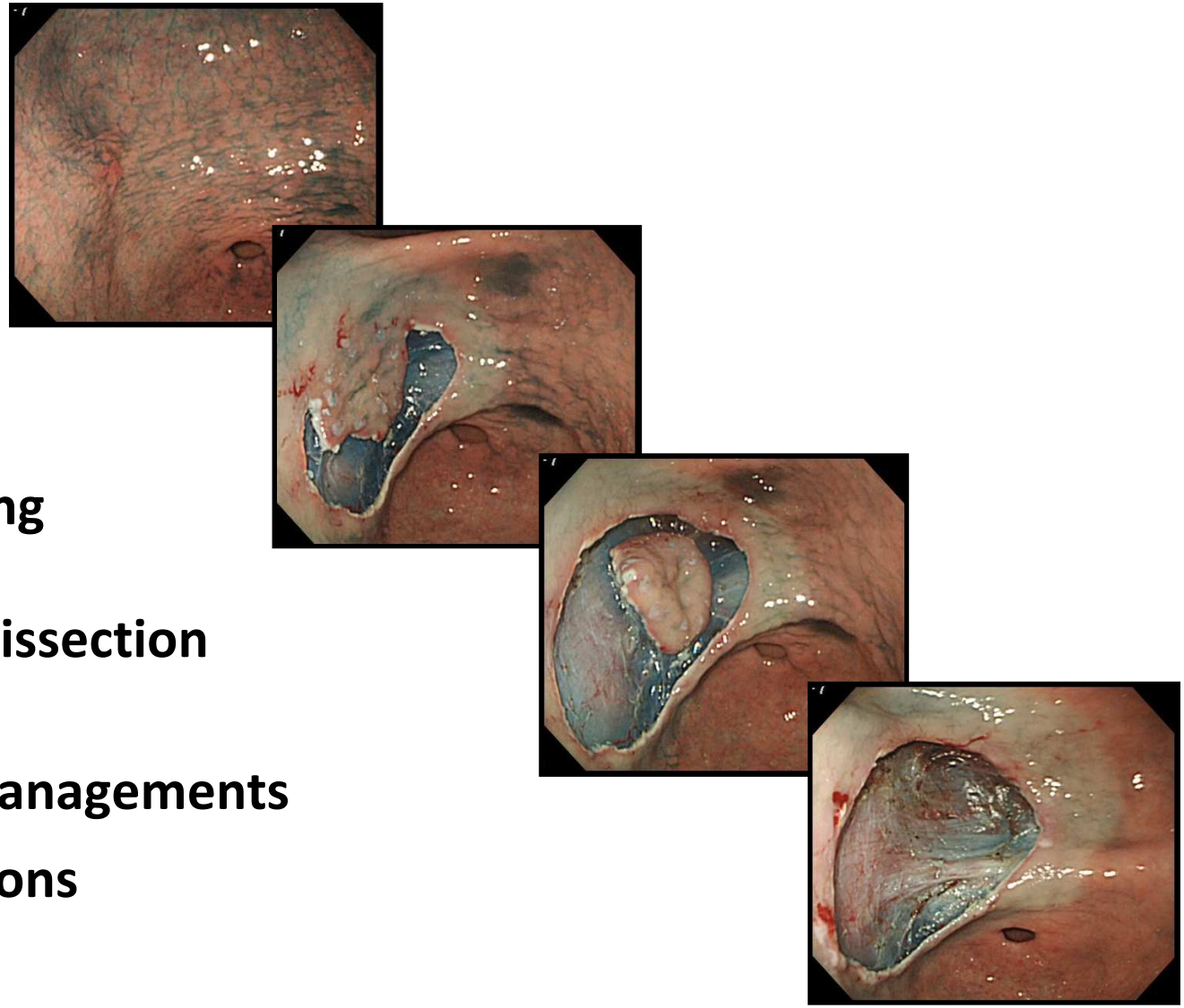

Endoscopic Submucosal Dissection (ESD)

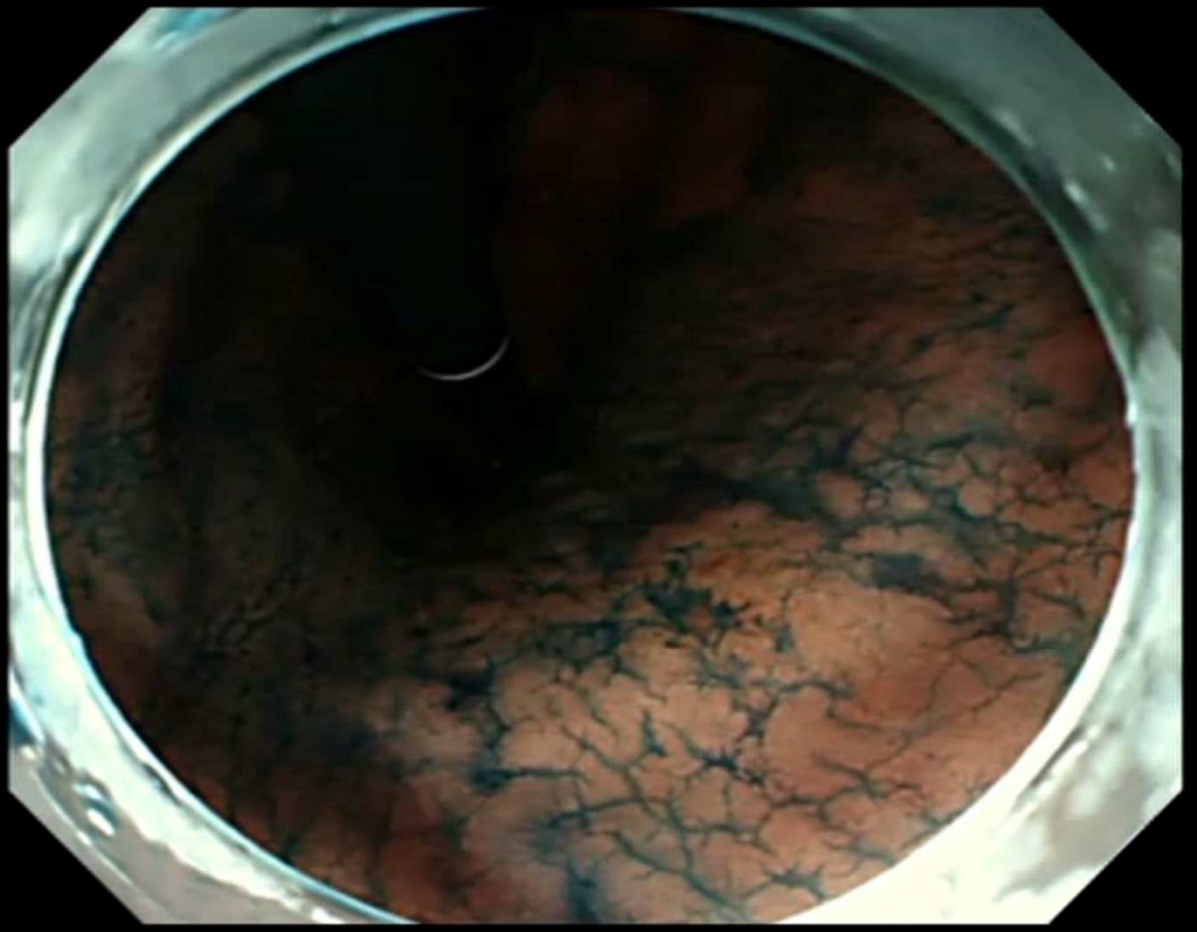

Indication of ESD for early gastric cancer

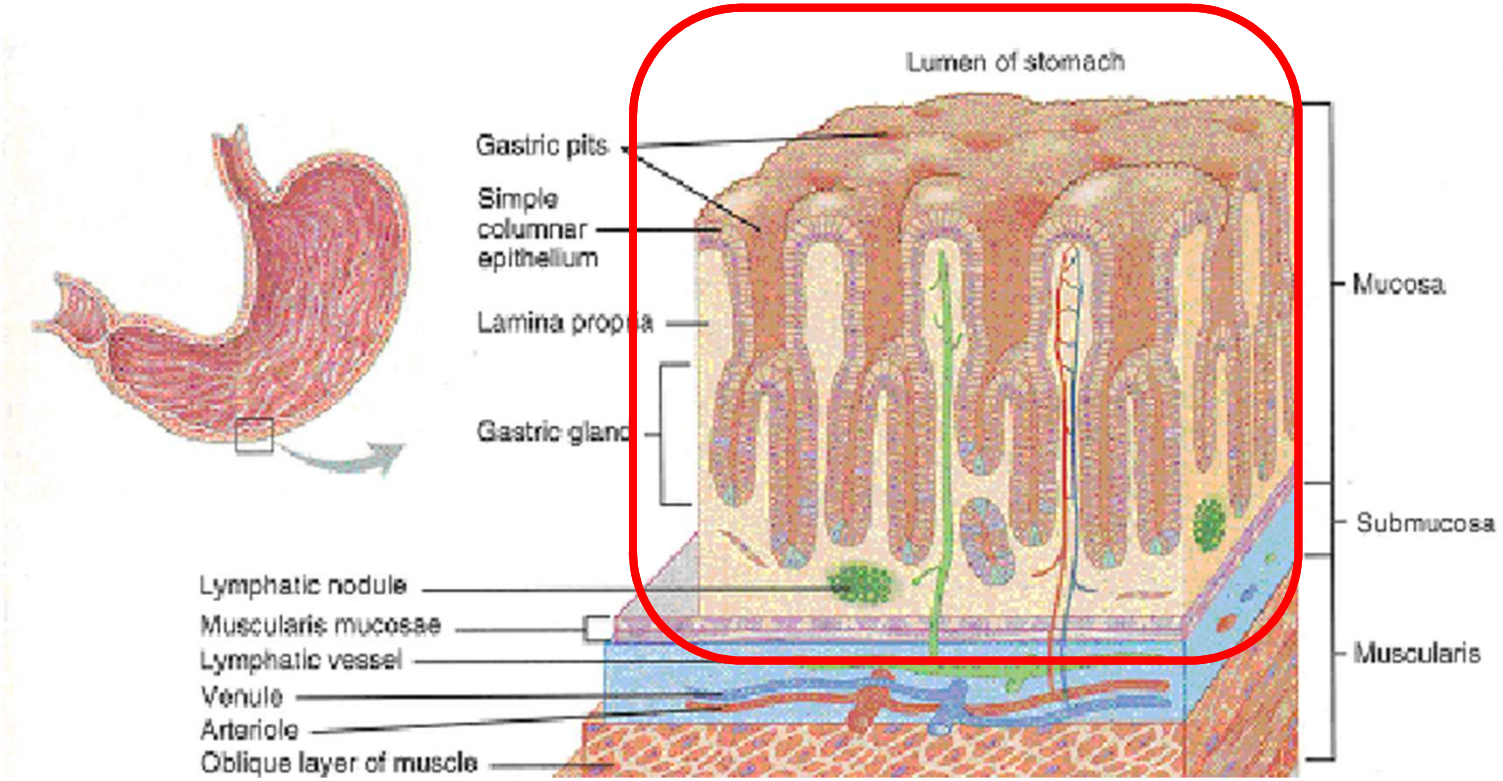

5-year survival rate after surgery for EGC

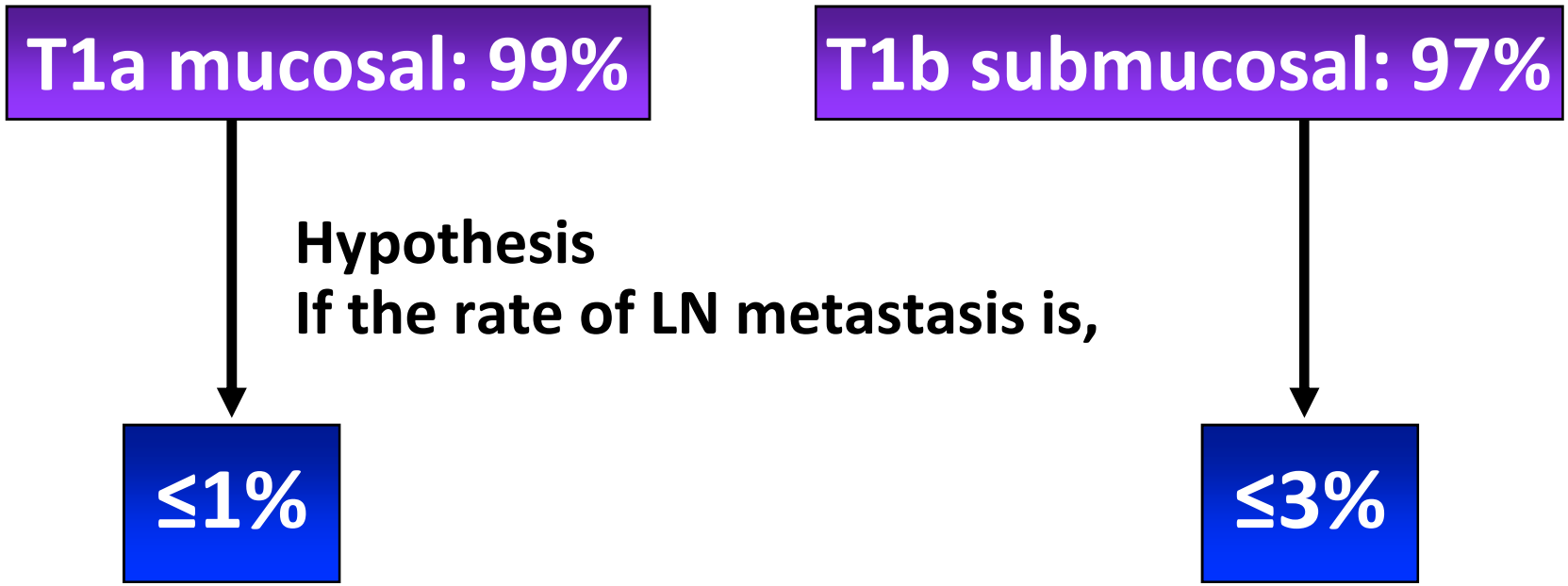

The curability of ESD is equivalent to surgery.

Sasako M, et al. Stomach and Intestine 1993.

EGC with low risk of lymph node metastasis

Depth	Ulceration	Differentiated type		Undifferentiated type	
pT1a (ly0,v0)	UL 0	≤ 2 cm	> 2 cm	≤ 2 cm	
		0% (0/437) 0 ~ 0.7 %	0% (0/493) 0 ~ 0.6 %	0% (0/310) 0 ~ 0.96 %	
	UL 1	≤ 3 cm			
		0% (0/488) 0 ~ 0.6 %			
pT1b (SM1) (ly0,v0)		≤ 3 cm			
		0% (0/145) 0 ~ 2.5%			

Risk of LN metastasis < 1%

Risk of LN metastasis < 1%

Risk of LN metastasis < 3%

Upper : % lymph node metastasis (%)
Lower : 95% confidence interval (CI)

Gotoda T, et al. Gastric Cancer 2000
Hirasawa T, et al. Gastric Cancer 2009

Gastric Cancer
DOI 10.1007/s10120-017-0704-y

ORIGINAL ARTICLE

A non-randomized confirmatory trial of an expanded indication for endoscopic submucosal dissection for intestinal-type gastric cancer (cT1a): the Japan Clinical Oncology Group study (JCOG0607)

Noriaki Hasuike[1] · Hiroyuki Ono[2] · Narikazu Boku[3] · Junki Mizusawa[4] · Kohei Takizawa[2] · Haruhiko Fukuda[4] · Ichiro Oda[5] · Hisashi Doyama[6] · Kazuhiro Kaneko[7] · Shinichiro Hori[8] · Hiroyasu Iishi[9] · Yukinori Kurokawa[10] · Manabu Muto[11] · Gastrointestinal Endoscopy Group of Japan Clinical Oncology Group (JCOG-GIESG)

Received: 8 December 2016 / Accepted: 7 February 2017
© The International Gastric Cancer Association and The Japanese Gastric Cancer Association 2017

Depth	Ulceration	Differentiated type		Undifferentiated type	
pT1a (ly0,v0)	UL -	≤ 2 cm	> 2 cm	≤ 2 cm	
		0% (0/437)	0% (0/493)	0% (0/310)	
		0 ~ 0.7 %	0 ~ 0.6 %	0 ~ 0.96 %	
	UL +	≤ 3 cm			
		0% (0/488)			
		0 ~ 0.6 %			
pT1b (SM1) (ly0,v0)		≤ 3 cm			
		0% (0/145)			
		0 ~ 2.5%			

Overall survival (OS)

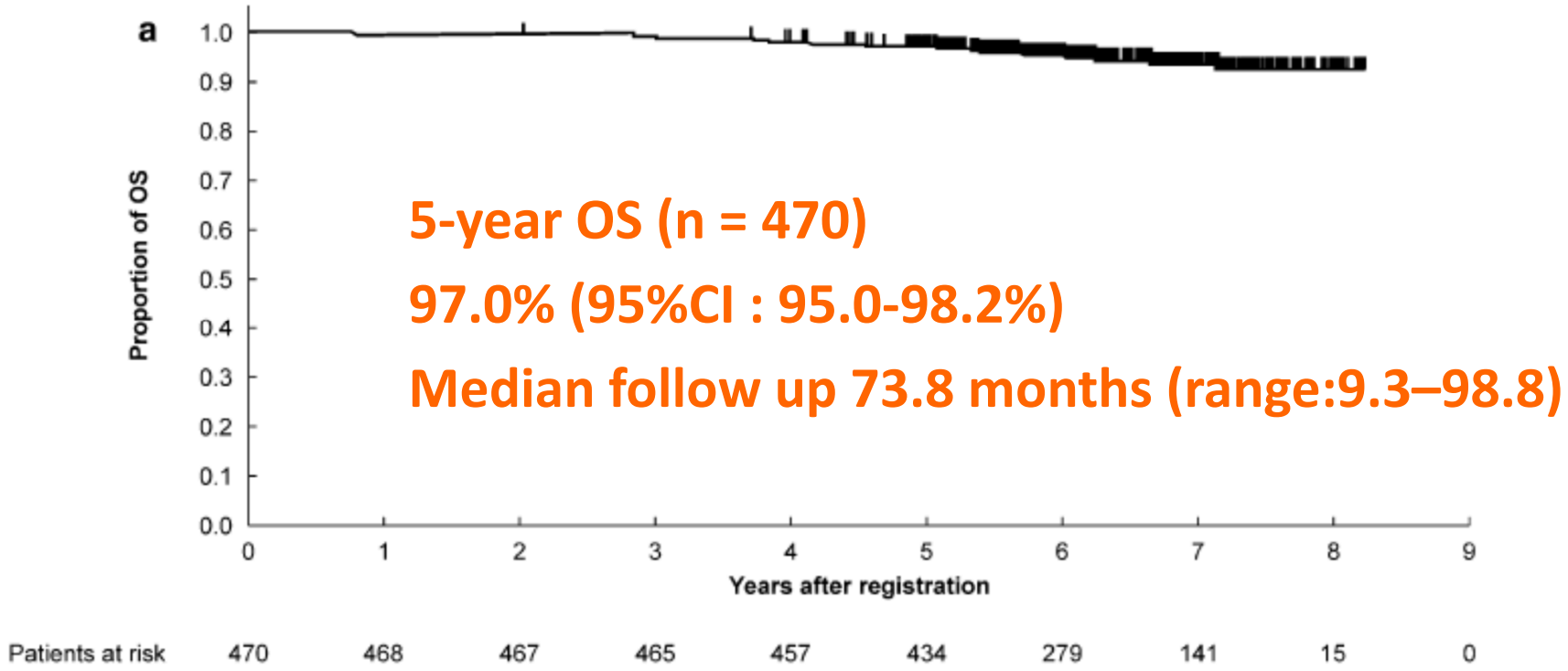

5-year OS (n = 470)

97.0% (95%CI : 95.0-98.2%)

Median follow up 73.8 months (range:9.3–98.8)

- **5-year OS of enrolled patients exceeded the age and sex adjusted 5-year OS in the general Japanese population.**
- **Null hypothesis was rejected because lower 95%CI of 5-year OS exceeded the threshold value; 86.1% (general population).**

Definitions of curative resection

Depth	Ulceration	Differentiated type		Undifferentiated type	
pT1a	UL 0	≤ 2 cm	>2 cm	≤ 2 cm	
	UL 1	≤ 3 cm			
pT1b	SM1	≤ 3 cm			
	SM2				

Curative resection (Absolute)

Curative resection (Expanded)

Non-curative resection

1. R0 resection
2. No lymphovascular involvement

Japanese Gastric Cancer Treatment Guidelines Ver5

JJCO Japanese Journal of Clinical Oncology

Jpn J Clin Oncol 2013;43(1)87–91
doi:10.1093/jjco/hys189
Advance Access Publication 19 November 2012

Clinical Trial Notes

A Phase II Clinical Trial of Endoscopic Submucosal Dissection for Early Gastric Cancer of Undifferentiated Type: Japan Clinical Oncology Group Study JCOG1009/1010

Kohei Takizawa[1,*], Atsuo Takashima[2], Aya Kimura[2], Junki Mizusawa[2], Noriaki Hasuike[3], Hiroyuki Ono[1], Masanori Terashima[4], Manabu Muto[5], Narikazu Boku[6], Mitsuru Sasako[7] and Haruhiko Fukuda[2] for the Gastrointestinal Endoscopy Study Group (GIESG) and Stomach Cancer Study Group (SCSG) of the Japan Clinical Oncology Group (JCOG)

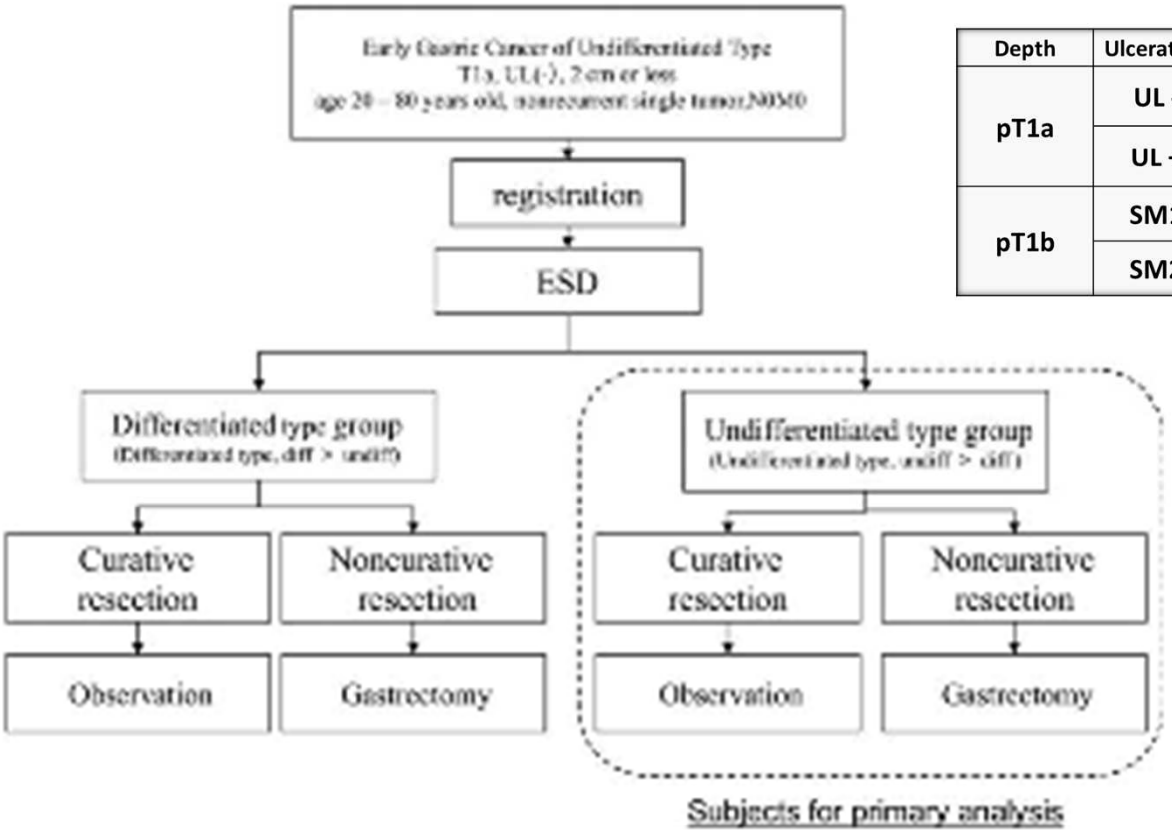

Depth	Ulceration	Differentiated type		Undifferentiated type	
pT1a	UL -	≤ 2 cm	>2 cm	≤ 2 cm	
	UL +	≤ 3 cm			
pT1b	SM1	≤ 3 cm			
	SM2				

Management of T1a early gastric cancer

- **Screening:** risk stratification and endoscopic diagnosis
- **Treatment:** endoscopic submucosal dissection (ESD)
- **Prevention:** *H. pylori* eradication after ESD

Main course of gastric carcinogenesis

Normal mucosa

↓

Active gastritis

↓

Chronic atrophic gastritis

↓

Intestinal metaplasia

↓

Gastric cancer

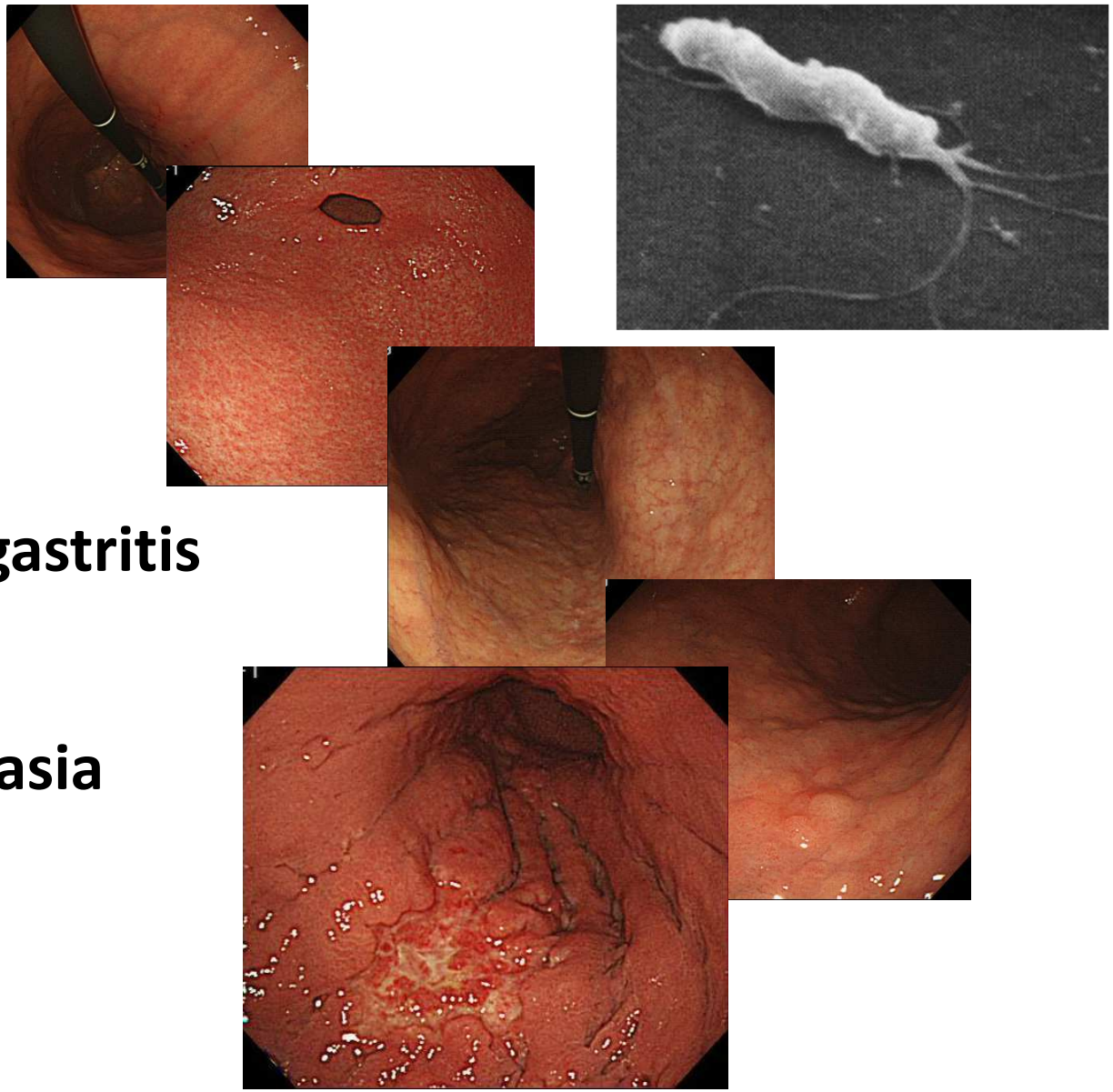

H. pylori eradication after ESD

Effect of eradication of *Helicobacter pylori* on incidence of metachronous gastric carcinoma after endoscopic resection of early gastric cancer: an open-label, randomised controlled trial

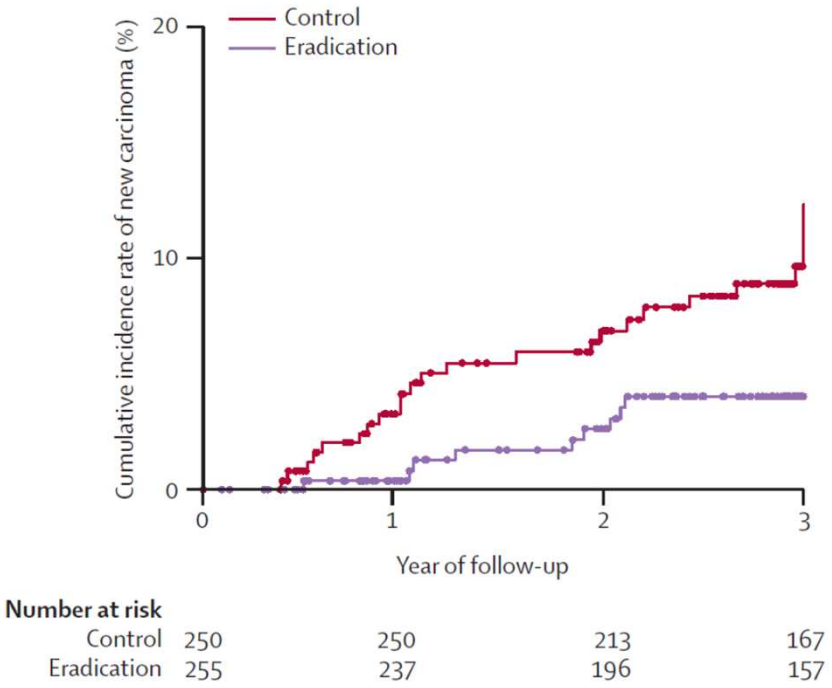

Number at risk				
Control	250	250	213	167
Eradication	255	237	196	157

Fukase K, et al. Lancet 2008.

Eradication of *Helicobacter pylori* After Endoscopic Resection of Gastric Tumors Does Not Reduce Incidence of Metachronous Gastric Carcinoma

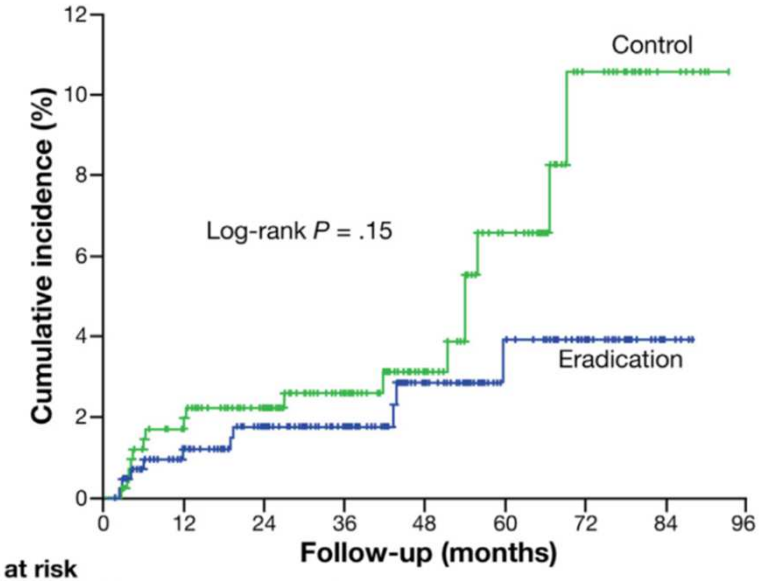

No. at risk									
Eradication	439	387	321	237	150	83	38	4	0
Control	441	373	305	221	136	78	39	9	0

Choi J, et al. CGH 2014.

The NEW ENGLAND JOURNAL of MEDICINE

ESTABLISHED IN 1812 MARCH 22, 2018 VOL. 378 NO. 12

Helicobacter pylori Therapy for the Prevention of Metachronous Gastric Cancer

Il Ju Choi, M.D., Ph.D., Myeong-Cherl Kook, M.D., Ph.D., Young-Il Kim, M.D., Soo-Jeong Cho, M.D., Ph.D., Jong Yeul Lee, M.D., Chan Gyoo Kim, M.D., Ph.D., Boram Park, M.S., and Byung-Ho Nam, Ph.D.

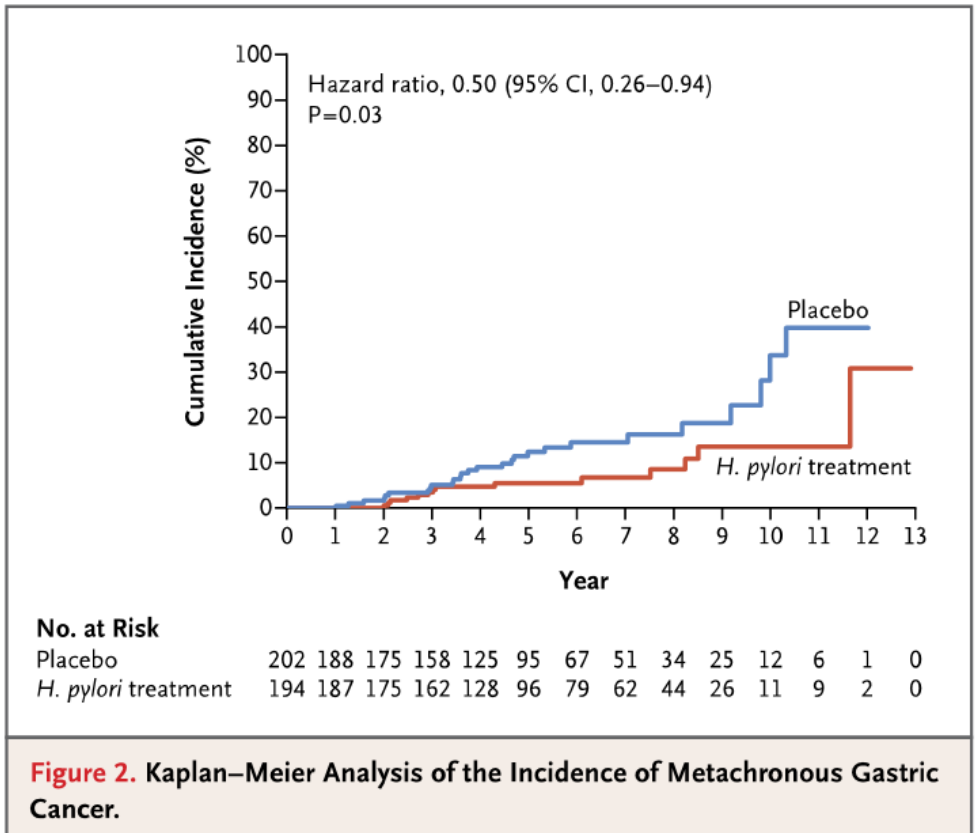

Figure 2. Kaplan–Meier Analysis of the Incidence of Metachronous Gastric Cancer.

Take home message

- **Supportive equipment IEE and AI are being developed for endoscopic diagnosis of early gastric cancer.**
- **Indication of ESD is established based on the rate of LN metastasis and the 5-year survival of surgical treatment.**
- ***H. pylori* treatment can reduce risk of metachronous gastric cancer after ESD.**

Nihon University Hospital

s.sho.salubriter.mail@gmail.com

NIHON UNIVERSITY