Local Complications in advanced prostate cancer

Lee Lui Shiong

Senior Consultant and Head of Service, Urology, Department of Surgery, Sengkang General Hospital

Senior Consultant, Department of Urology, Singapore General Hospital

Visiting Consultant, Surgical Oncology, National Cancer Centre

Adjunct Asst Professor, Dukes-GMS

Lee.lui.shiong@singhealth.com.sg

Singapore General Hospital
SingHealth

Sengkang Health
SingHealth

Disclosures

- Advisory board
  - Janssen
  - Bayer
  - MSD
  - BMS

- Clinical trial funding
  - Janssen

Practical approach

- Urinary Obstruction of the lower urinary and upper urinary tract

—

- ~~Cytoreductive prostatectomy~~
- ~~Salvage lymph node dissection~~

Prevalence

- High incidence of nodal metastasis to pelvis and retroperitoneum in advanced prostate cancer

- N=30-50 cases of metastatic / advanced cancer per year
  - High prevalence of BOO or hydronephrosis

Levels of obstruction

- Ureteric
  - Retroperitoneal nodes
  - Trigonal invasion
- Bladder outlet

Ureteric obstruction

- Diagnosis – imaging guided
- Common dilemma in ureteric obstruction
  - Unilateral obstruction
    - Intervene or not
  - Bilateral obstruction
    - Intervene one or both sides
    - Which side first?

Unilateral obstruction

- Not symptomatic
- No clinical intent for chemotherapy
- Limited life expectancy 1 year or less

- Patient preference, perceived QoL from intervention

- May not intervene

Unilateral obstruction

- Nephrostomy preferred over retrograde stent insertion
  - LA
  - More expedient in those that are symptomatic (sepsis)
- Can allow antegrade insertion of stent
- Retrograde insertion possible
  - Difficult -> GA
  - Manipulation may trigger sepsis

To stent or not?

- Bulky pelvic disease
  - Urethral access is difficult
  - Cannot change stents
  - Divert urine away from hostile area

Singapore General Hospital
SingHealth

Sengkang Health
SingHealth

Choice of stents

- Polymeric stents
- Soft material
- Side holes allow urine flow
  - Can get encrusted
- Change via retrograde route is easy
- Better comfort profile

- Metallic stents
  - Resonance (Boston)
  - Less frequent change (12 months)
  - Discomfort



- Thermoexpandable memory stents
  - cost

Bilateral obstruction

- Drain the symptomatic side first
- Drain the side with better functional parenchyma

- Then consider the other side in the clinical context

Bladder outlet obstruction

- Urethral catheter or SP catheter is most expeditious especially in ARU
- Consider channel TURP
  - Surgically fit
  - Desires short catheter time
- Select patient with cT3 disease in retention – RP

Channel TURP for BOO

- More efficacious than ADT alone to relieve BOO expediently
- Higher risk of incontinence (5%) and need for re-intervention compared to TURP for BPH
- Higher risk of initial failed TOC (up to 20%)
  - bulky disease
  - Neurological compromise

Singapore General Hospital
SingHealth

Urology 1991;38:526–528.
J Urol 2002;167:5–9.

Sengkang Health
SingHealth

Channel TURP for BOO

- Higher incidence of stress urinary incontinence after TURP and RT

- May have to delay RT until continence stabilises

Singapore General Hospital
SingHealth

Urology 1991;38:526–528.
J Urol 2002;167:5–9.

Sengkang Health
SingHealth

Bladder outlet obstruction

- Not suitable for TURP
  - Upfront ADT
  - 80-90% catheter free – 6 months
  - LHRH agonists, anti androgens, orchidectomy : no difference to catheter free time

  - Suprapubic catheter over urethral catheter
    - Comfort
    - Difficult urethral access

Urology 1985;25:354–356
J Urol 1985;134:498–500.

Is there a role for radical surgery?

- 65 year old retired home builder
- Taking care of grandchildren
- Acute retention of urine
- O/E DRE large , benign
- PSA 1.5

- CT Urogram showed a large prostate about 60ml, heterogenous mass

Singapore General Hospital
SingHealth

Sengkang Health
SingHealth

- TURP – poorly differentiated tumour
- positive cytokeratin AE1/3, AR
- PSA is very focally positive , PSAP is negative
- focal expression of GATA-3
- Uroplakin, 34BetaE12, p40 and p63 are negative (urothelial)

- Advised for radical treatment but defaulted for 3 months as no more urinary symptoms
- Represented with haematuria
- MRI – local progression to involve trigone , possibly rectum, new left hydronephrosis

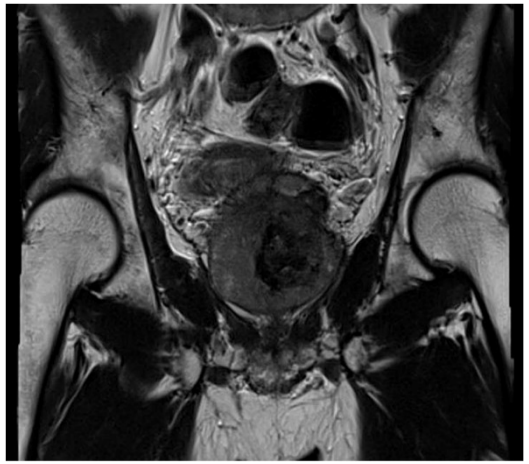

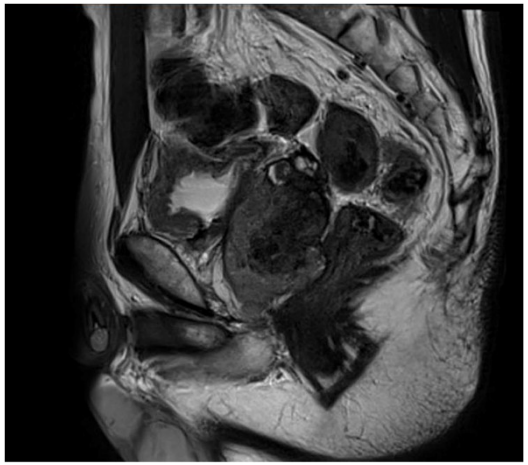

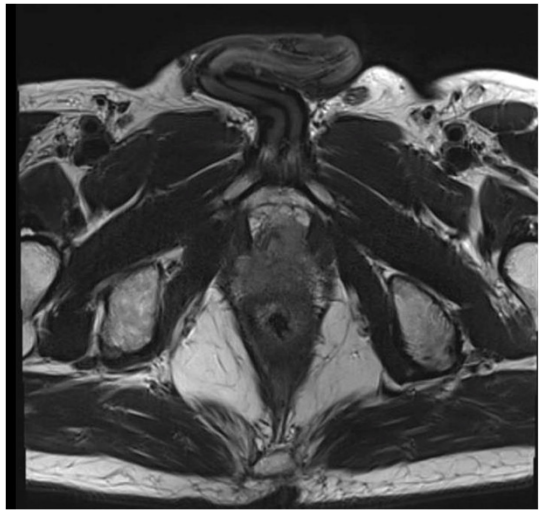

Singapore General Hospital
SingHealth

Sengkang Health
SingHealth

- PSMA PET
  - Primary tumour uptake of PSMA
  - No distant mets

- Histology reviewed by uro pathologist in SGH
  - Likely prostatic origin
  - Poorly differentiated
  - Agree with immunostains of previous report
  - Unlikely urothelial

- Multidisciplinary clinic
  - Curative intent but need multi-modality therapy
  - ? Role of androgen deprivation therapy

  - Neoadjuvant bicalutamide+ LHRH agonist + surgery + adjuvant RT
  - Neoadjuvant LHRH + RT
  - ? Role of docetaxol, abiraterone

- Intra-operative findings
  - Large prostate tumour involving trigone, extended out of posterior peritoneum at rectovesical pouch
  - Rectum adherent close to apex

  - Primary rectal closure, defunctioning colostomy
  - Ileal conduit
  - VRAM flap to anterior pelvis

- Histology
  - pT4 Gleason 5+5 , 0/31 nodes negative
  - Urethral margin negative
  - Posterior margin positive (peritoneum involved)
  - Rectal margin negative
- Discharged POD 7

- Started leuprolide and adjuvant RT 1 month later

- First post Sx+Adjucant RT PSMA - negative

Urological outcomes following pelvic exenteration for advanced pelvic cancer are not inferior to those following radical cystectomy

Edwin J. Aslim, Min Hoe Chew, Ghee Kheng Chew, Lui Shiong Lee

First published: 12 June 2018 | https://doi.org/10.1111/ans.14689

- 22 pelvic exenteration cases
- 2013-2016
- No anastomotic leaks
- Stricture / obstruction of ureter – 5% from extrinsic node recurrence

Summary

- Ureteric obstruction
  - Intervention should be clinically meaningful
  - Don't treat the scans alone!
  - PCN versus stents

- Bladder outlet obstruction
  - Channel TURP is efficacious but less so than TURP for BPH
  - ADT then TOC is possible with a longer catheter time
- Selected patients for exenteration