GOOD SCIENCE
BETTER MEDICINE
BEST PRACTICE

ESMO Preceptorship Programme

Head and Neck cancer – Zurich, Switzerland – 22-23 May 2018

Duarte Machado
Clinical Oncology Trainee
Institute of Oncology ate Lisbon - Portugal

Head and neck cancer – What's the best approach for elderly patient?

Disclousers

- No conflict of interest

ESMO GOOD SCIENCE BETTER MEDICINE BEST PRACTICE

Initial presentation

- Case History:
  - Male patient, 70 yrs,
  - Smoker, alcoholic, PS ECOG 1
  - No comorbidities
- Clinical symptoms:
  - Odinophagy and disphagy since1 year
  - **ENT work-up, Head and Neck CT (04/2010), X- Ray**

ESMO GOOD SCIENCE BETTER MEDICINE BEST PRACTICE

Diagnosis and Staging

- **ENT examination**:
  - mass in posterior hypopharynx extensive to laryngeal wall
  - No nodules enlargement;

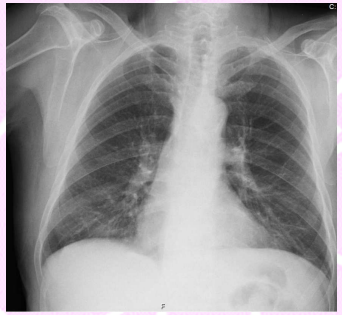

→ **Biopsy: Moderatly differenciated SCC, G2**

- **Head and neck CT:**
  - Extensive infiltrative mass expression of the posterior wall and right lateral postero of the oro / hypopharynx (4 x 3 cm)
  - infiltrative aspects of the retro-pharyngeal space and pre-vertebral muscles, extending anterolaterally to the posterior wall of the right pyriform sinus and paraglottic space in contiguity, without involvement of the tiro-aritenoideu gap.
  - No nodes enlargement;

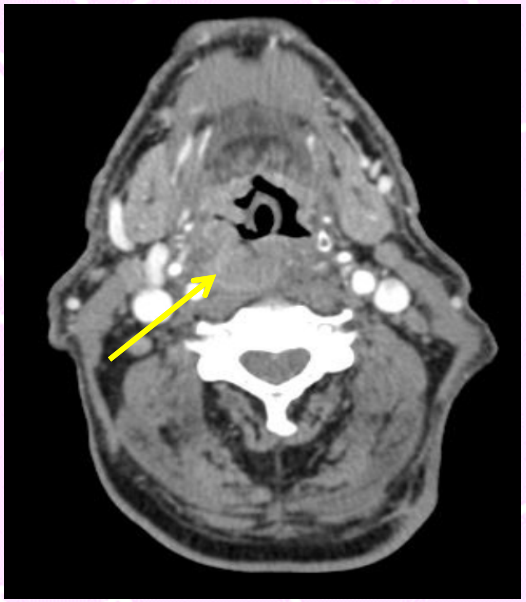

- **X-Ray** – normal
- Blood test: Clcreatinine= 78,99 ml/min

ESMO GOOD SCIENCE BETTER MEDICINE BEST PRACTICE

Treatment

- **Stage IV – cT4 cN0 M0**
  - **Definitive Chemoradiotherapy**
    - High-dose Cisplatin ?
    - Weekly Cisplatin 40mg/m2
    - Carboplatin / infusional 5-FU?
    - Cetuximab ?

?

- **IMRT + Cetuximab loading dose 400mg/m2 » 250mgm/2 weekly**

07/2010 to 09/2010

2010 — Complete remission — 2017

ESMO GOOD SCIENCE BETTER MEDICINE BEST PRACTICE

GOOD SCIENCE
BETTER MEDICINE
BEST PRACTICE

ESMO Preceptorship Programme