Shikha Goyal
Division of Radiation Oncology,
Medanta The Medicity, Gurugram, INDIA

# Hepatocellular carcinoma with portal venous tumour thrombus: SBRT as neoadjuvant therapy

# Case details

## Presentation

- 56 year male; No comorbid conditions, No alcohol use
- Fatty liver since 4 years. Viral markers negative
- Upper GI variceal bleed in January 2017 (Endoscopy showed grade 2 varices. needing endoscopic ligation)

## Investigations

- AFP 4470
- Blood counts, Liver function, Renal function tests normal
- PET-CT (02.02.17): Chronic liver disease. Ill-defined hypodense lesion in segment VI / VII of liver, contiguous extension as FDG avid thrombus within right anterior/right posterior/left/main portal vein. FDG avid lesion ?node within right parotid gland.
- FNAC parotid SOL: pleomorphic adenoma

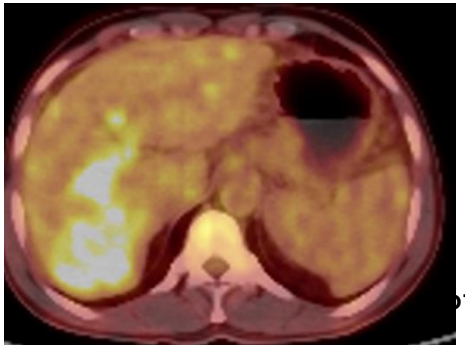

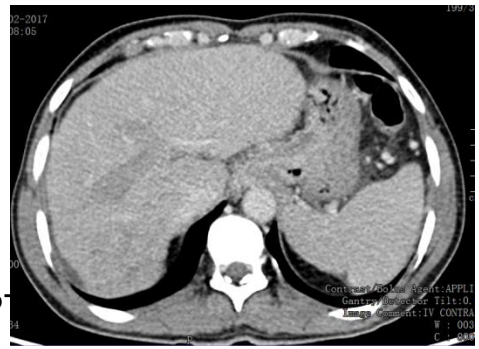

ESMO GOOD SCIENCE BETTER MEDICINE BEST PRACTICE
European Society for Medical Oncology

# Initial therapy and evaluation

**Initial therapy**

- Underwent TACE at another facility on 14.02.17
- Post-TACE transaminitis/fever/Upper GI bleed: conservative management
- Consulted liver transplant team at our institution

***Evaluation***

- ECOG 1
- Child Pugh B
- Liver cirrhosis MELD 13
- Hepatocellular carcinoma Stage C (BCLC)
- Portal vein tumour thrombus: Liver cancer study group, Japan grade Vp4 (projected 5y survival 18%)
- Outside "Milan criteria" for liver transplant
- Platelets 127,000, INR 1.19, Total bilirubin 1.1, direct 0.7)
- SGOT/SGPT/SAP 89/50/166; Albumin 3.3



European Society for Medical Oncology

# Treatment options discussed

- Palliative: Sorafenib or Best supportive care
- Stereotactic body radiation therapy to portal venous tumour thrombus followed by assessment for portal vein recanalization and possible candidature for liver transplant in case of good response
- Patient opted for latter approach

# Post TACE, pre-SBRT imaging

- Dynamic CT liver 6 weeks post-TACE: Sequelae of chronic liver disease and portal hypertension. Lipiodol in posterior segment of right lobe of liver (segment 7,8), representing residual mitotic disease/HCC. Few minimally enhancing nodular lesions with definite washout on venous phase in segments 5 & 8, suggestive of multicentric HCC. Enhancing tumor thrombus in RPV, LPV and MPV reaching upto its mid part. Tail of likely bland thrombus in the distal MPV, splenoportal confluence and distal SMV

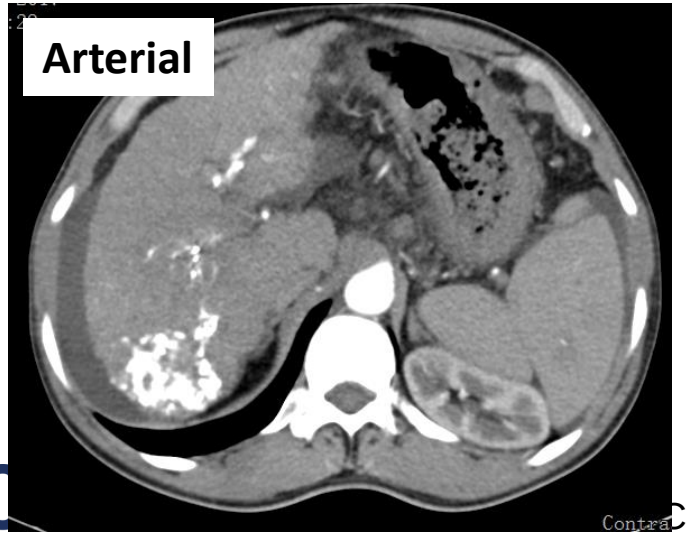


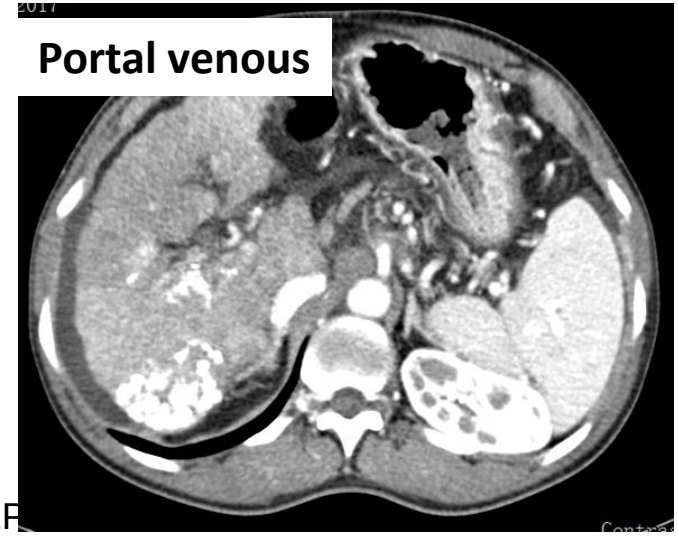

# SBRT - 1

- Volumetric study of liver
  - Total liver volume with tumor: 868 cc
  - Total tumor volume: 254 cc
  - Non-tumor liver: 614
- SBRT was planned with CyberKnife
- A dose of 39 Gy in 3 fractions to PVTT was planned and delivered

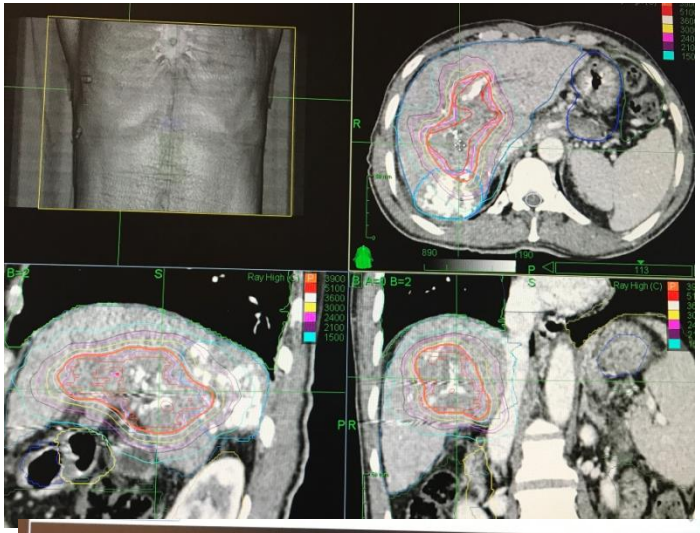

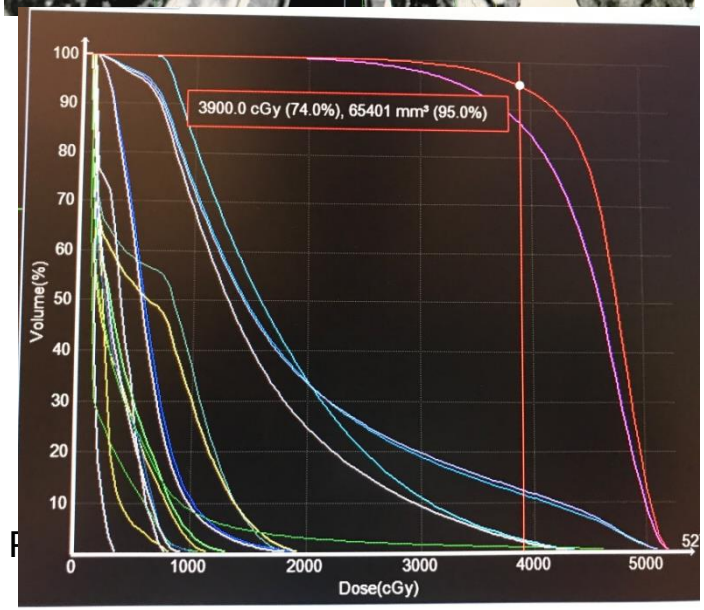




GOOD SCIENCE
BETTER MEDICINE
BEST PRACTICE
European Society for Medical Oncology

# Post-SBRT-1 response

- PET-CECT (6 weeks post SBRT-1):Persistent portal hypertension sequelae. Multicentric liver nodules as before. Partial reduction in extent and enhancement of PVTT. Tail of partial bland thrombus within the main portal vein, splenoportal confluence and distal SMV

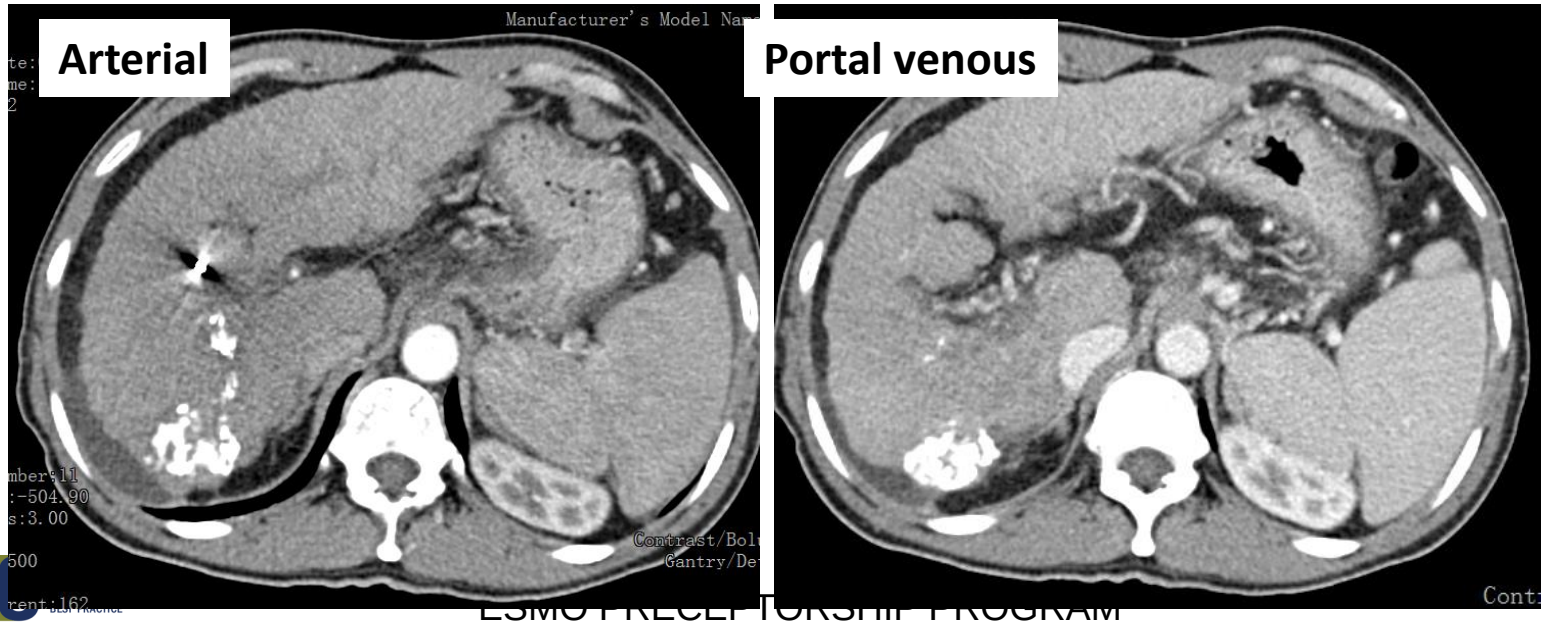

# SBRT - 2

- Reassessed by Liver transplant team.
- Partial recanalization of thrombus
- Discussed in MDT
- Decided to offer another session of SBRT to residual PVTT before proceeding with Liver transplant.
- After accounting for change in liver (increased) and tumor size (reduction) as well as dose decay from previous radiation, he was given a dose of 35 Gy in 5 fractions (central dose ~60 Gy in 5 fractions) to residual PVTT

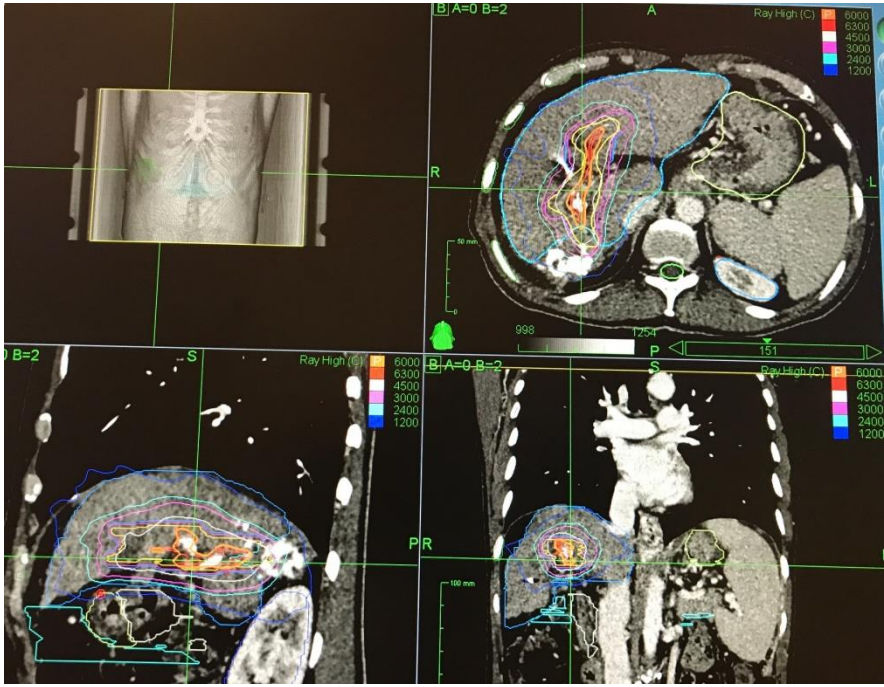


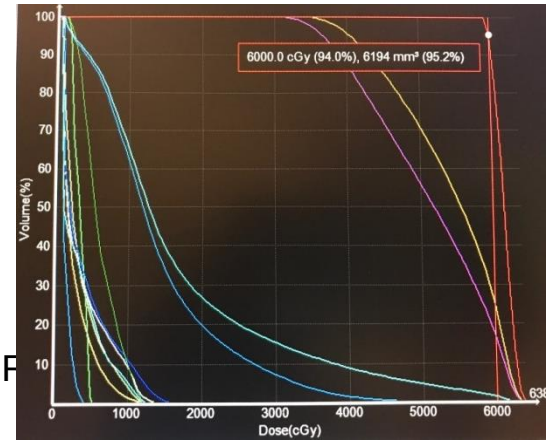




ESMO GOOD SCIENCE BETTER MEDICINE BEST PRACTICE
European Society for Medical Oncology

# Post-SBRT-2 response

- PET-CECT (6 weeks post SBRT-2): Chronic liver disease/multinodular HCC persisting though reduced in size. Tumor thrombus in RPV, LPV reaching up to mid MPV; showing no significant enhancement with no significant FDG uptake. Tail of likely bland thrombus in distal MPV involving spleno-portal confluence and distal SMV seen as before. No other significant extra-hepatic disease.

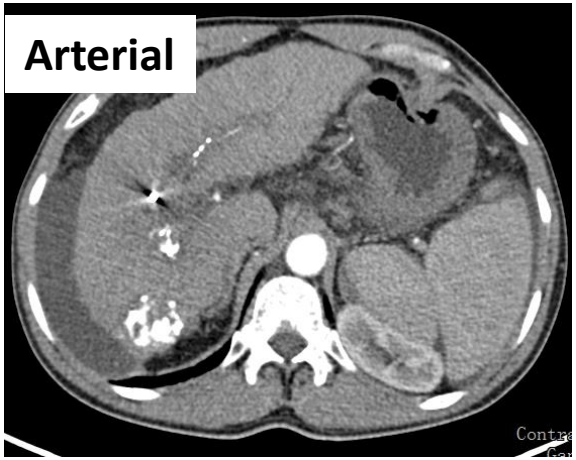


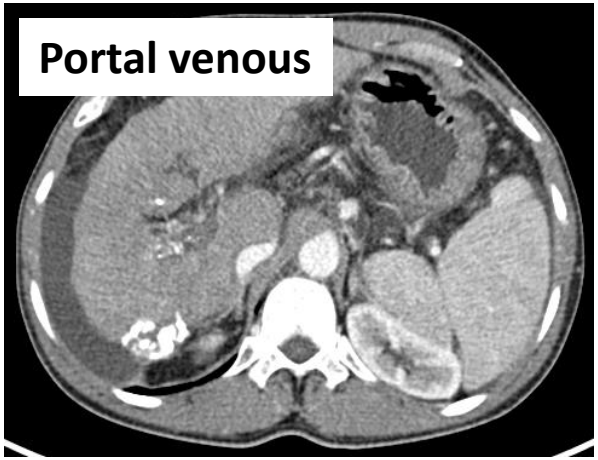


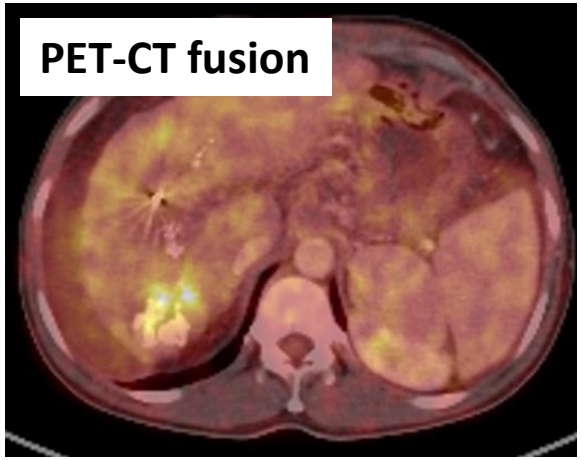


Serum AFP: 998

Blood counts and liver function parameters within normal limits

Patient is at present being evaluated for feasibility of liver transplant. Else, would need to start systemic therapy with Sorafenib

# Conclusion

- SBRT for PVTT is a novel approach and offers a curative option (~40-50% chance of recanalization) for non-metastatic HCC patients who are not candidates for transplant upfront
- Patients whose liver reserves improve on local therapy and have partial response to initial therapy may rarely be candidates for re-SBRT
- Caution is advocated to avoid radiation induced liver disease

- In our own experience of 42 cases of HCC with PVTT treated between April 2011 and March 2017 with SBRT, 13 have undergone transplant and 14 are awaiting assessment for the same. Of these, 4 needed repeat SBRT for consolidation of response in PVTT