Joana Simões
Medical Oncology Department, Centro Hospitalar de São João
Porto, Portugal

Metastatic Castration-Resistant Prostate Cancer

the challenge of a patient with Chronic Kidney Disease

Identification

Male, 57 years old. ECOG PS 0.

Personal Past History

Heavy smoker.

No other known disease or cardiovascular risk factors.

No usual medication. No drugs or food allergies.

No family history of oncologic disorders.

History of Presenting Illness

March 2009

- Hospital admission with **obstructive acute renal failure** → percutaneous nefrostomy
- Renal-pelvic ultrasonography: **enlarged and heterogeneous prostate**
- PSA: **250 ng/mL**

- Transrectal core prostate biopsy: **prostatic acinar adenocarcinoma Gleason 8 (4+4)**
- CT scan: **metastatic bone lesions** (dorsal-lumbo-sacral spine and pelvic)
- Bone scan: **diffuse metastatic bone lesions**

cT4 Nx M1b, Gleason 4+4

Bilateral subalbuginea orchiectomy

PSA **26.34 ng/mL**

ESMO GOOD SCIENCE BETTER MEDICINE BEST PRACTICE
European Society for Medical Oncology

June 2009

- Renal function deterioration → **Hemodialysis**
- Multidisciplinary decision**:** surveillance

March 2014

CASTRATION-RESISTANT PROSTATE CANCER

- **Clinical progression**: severe bone pain
- **Biochemical progression:** PSA 768 ng/mL
- **Radiologic progression**: bone scan with more lesions (parietal, right scapula, D4-5, 6 -7th left costal ribs and right iliac)

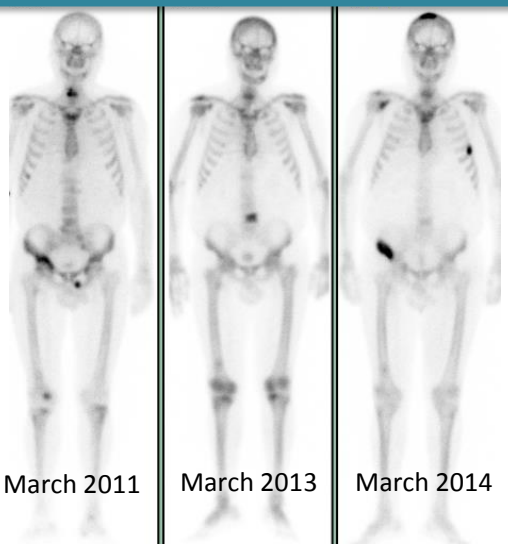

- Multidisciplinary decision:

  Chemotherapy with **Docetaxel** 75 mg/m² ev (21-21 days) + Prednisolone 10 mg/day

  Bisphosphonate therapy with **Zoledronic Acid** (dose reduction) → suspended in September by hipoCa2+

  Adverse events: peripheral sensory neuropathy, grade 1

  Antalgic radiotherapy to the **dorsolombar spine** (D3-5 and D11-L4), total doses 30Gy

January 2015

- Completed 10 cycles of chemotherapy with **stable disease**
- PSA **231 ng/mL**

March 2015

Disease Progression

- **Clinical progression**: worse bone pain
- **Biochemical progression:** PSA 318 ng/mL
- **Radiologic progression**: bone scan with more lesions
  (+ 8-11th left costal ribs and right pubis)

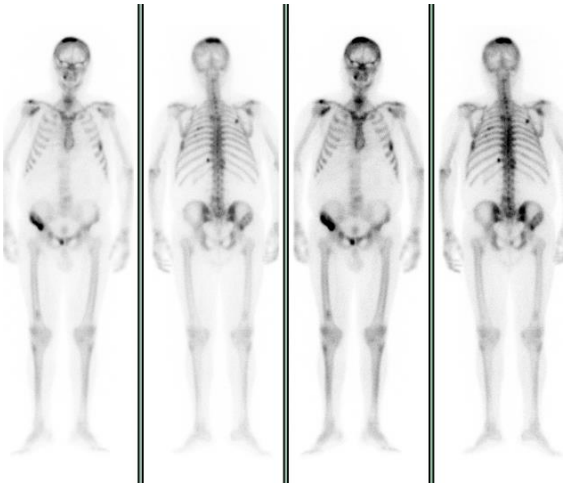

- Multidisciplinary decision:
  2nd line treatment with **Enzalatumide** 160 mg/day
  Adverse events: not significant

March 2016

- Cerebral CT: **parietal osteoblastic metastasis**
- Multidisciplinary decision: **External Radiotherapy**, total doses 30 Gy

July 2016

- PSA **3,9 ng/mL**
- CT scan and bone scan with **stable disease**

December 2016

Disease Progression

- **Biochemical progression:** PSA 217 ng/mL
- **Radiologic progression**: new bone metastasis (+3º, 6º, 7º e 11º right costal ribs)

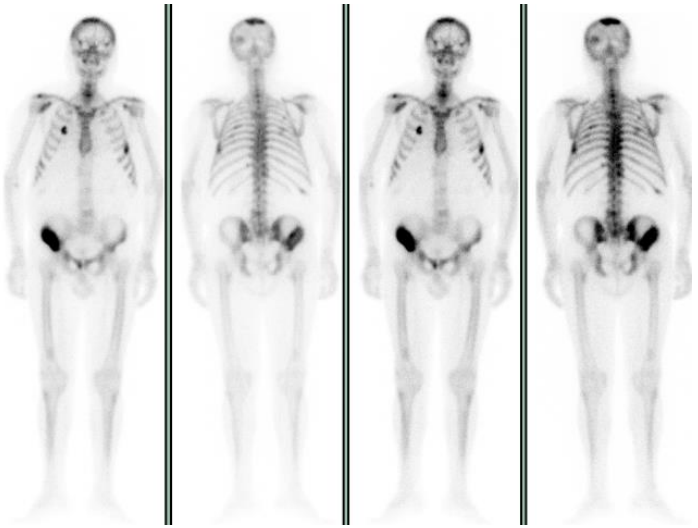

- Multidisciplinary decision:
  3nd line treatment with **Radium-223**
  Adverse events: not significant

August 2017

Completed 6 cycles of Radium-223 in 22/08/2017.

Adverse events: none.

- **Clinical**: no pain.
- **Biochemical:** PSA 405 >>> 2096 > 2364 > 1938 ng/mL.
- **Radiologic**: - Bone scan: new lesions in frontal bone, 4-5th left costal ribs, 8th right and left costal rib, sternum, right and left femur; less intensity of previous parietal, costal ribs and iliac lesions.
  - CT: stable metastatic bone lesions, without more changes.

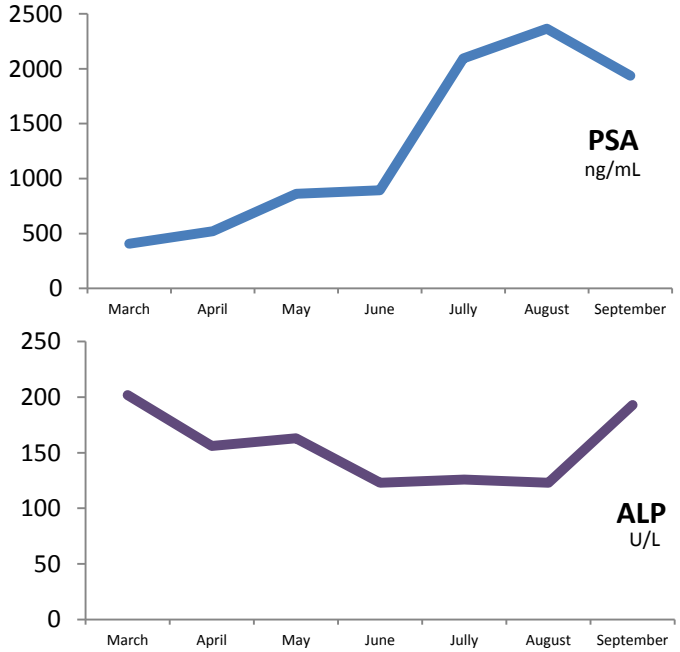

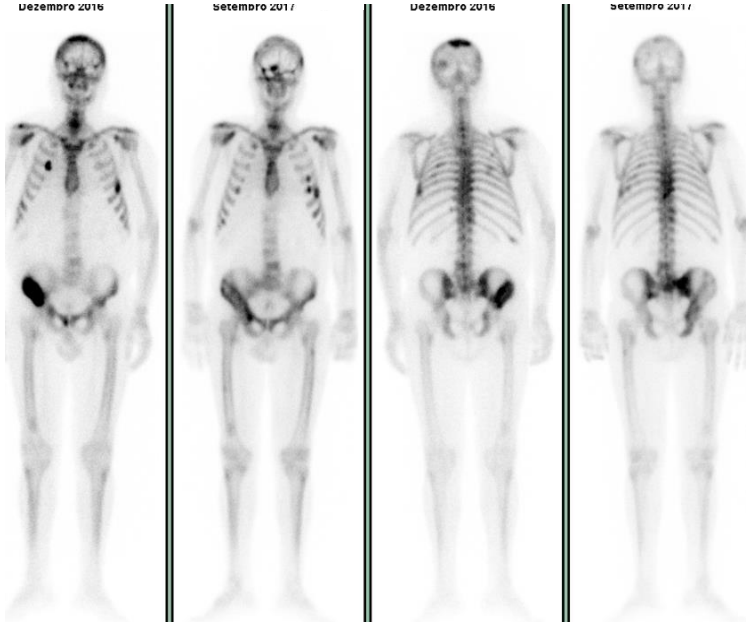

Discussion

- The importance of a **multidisciplinary decision** in this type of patients in hemodialysis with several therapeutic interactions and the need to adjust treatment
  - Experience with patients in hemodialysis? Which drugs?
- Do you consider **other therapeutic sequence**?
- Any consideration about the **current patient situation with Radium-223**?
  - Value of **PSA** and **ALP** as **biomarkers** for treatment response?
  - **Timing** of **biochemical** and **radiologic revaluation**?
  - **PSA flare**? **Scintigraphic flare**?

... and thank you for your attention!