The Evolution of RT Techniques for Gynaecological Cancers in a developing country context

Hannah Simonds

Stellenbosch University/ Tygerberg Academic Hospital

ESMO Africa 2017

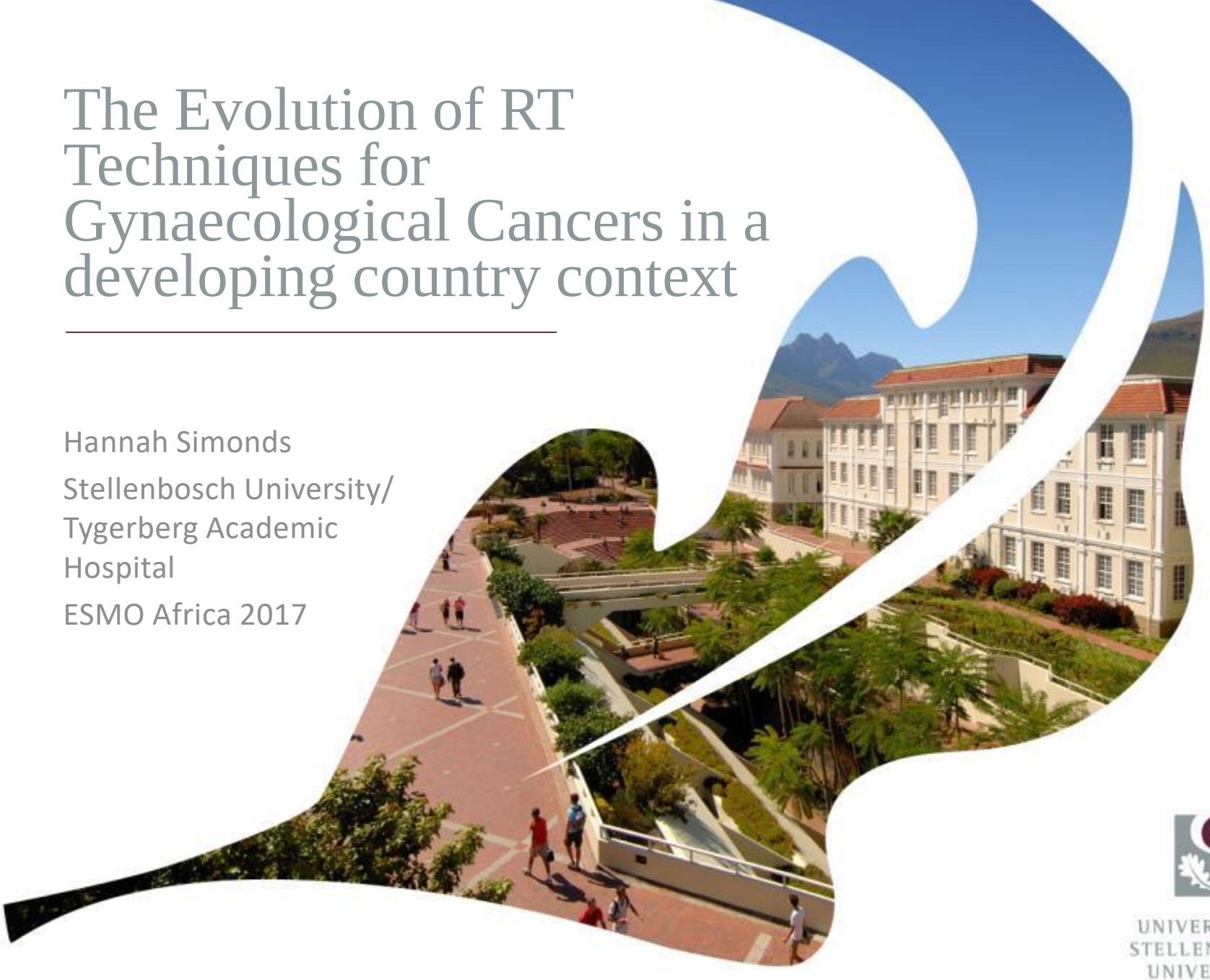

UNIVERSITEIT STELLENBOSCH UNIVERSITY

I have no disclosures

UNIVERSITEIT
STELLENBOSCH
UNIVERSITY

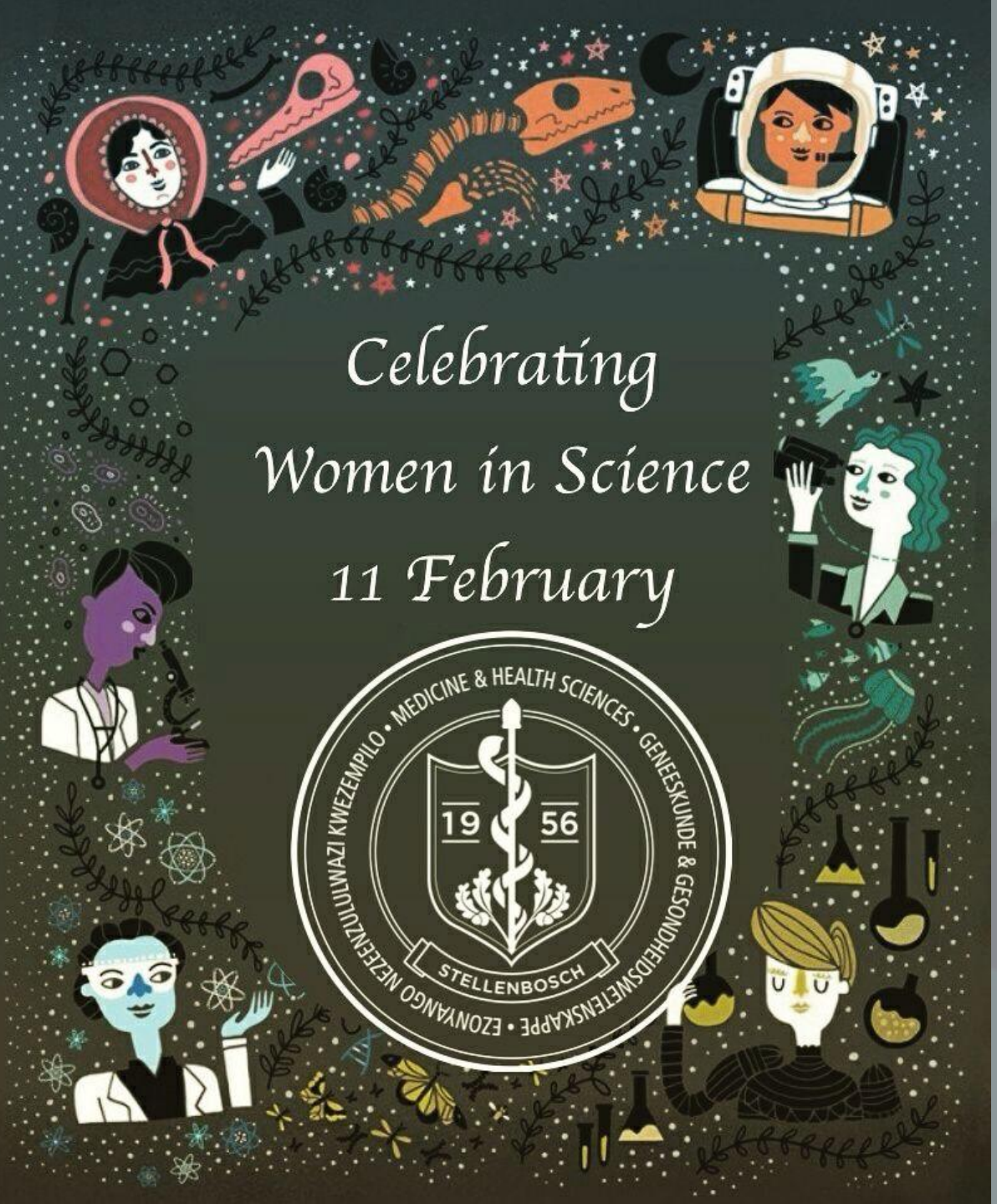
Celebrating
Women in Science
11 February
MEDICINE & HEALTH SCIENCES • GENEESKUNDE & GESONDHEIDSWETENSKAPPE • EZONYANGO NEZEENZULULWAZI KWEZEMPILO
19 56
STELLENBOSCH

External beam radiotherapy

UNIVERSITEIT
STELLENBOSCH
UNIVERSITY

Where did we start…

Started with AP/PA opposing fields

Conventional treatment 4 field box technique.

Covering primary and draining nodes

Simulation field using bony landmarks.

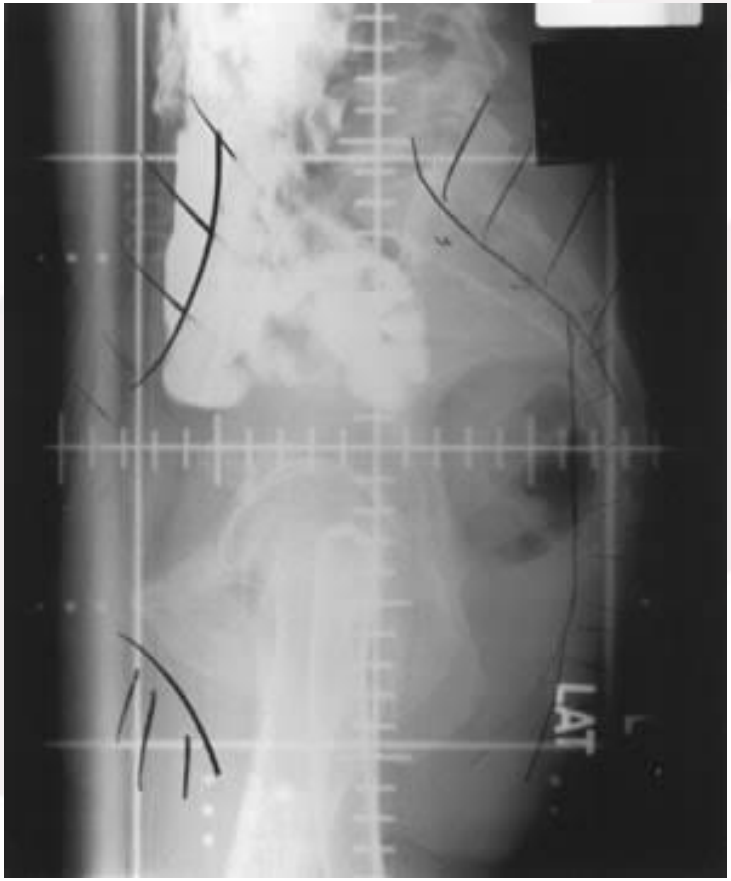

Simulator planning

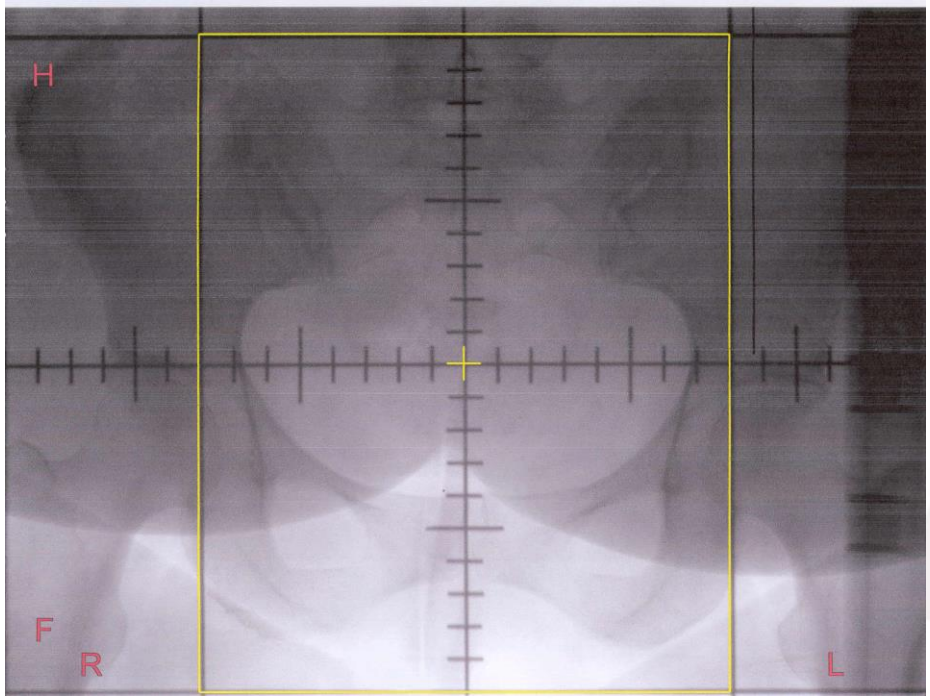

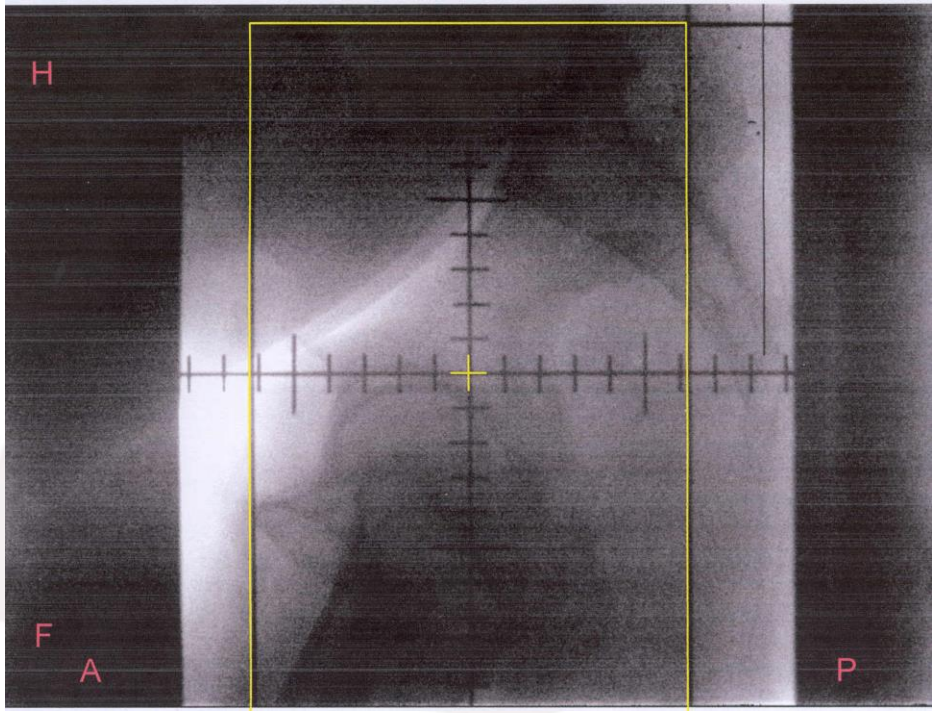

Fig 3. Standard anterior external-beam irradiation port used to treat locally advanced cervical carcinoma limited to the pelvis

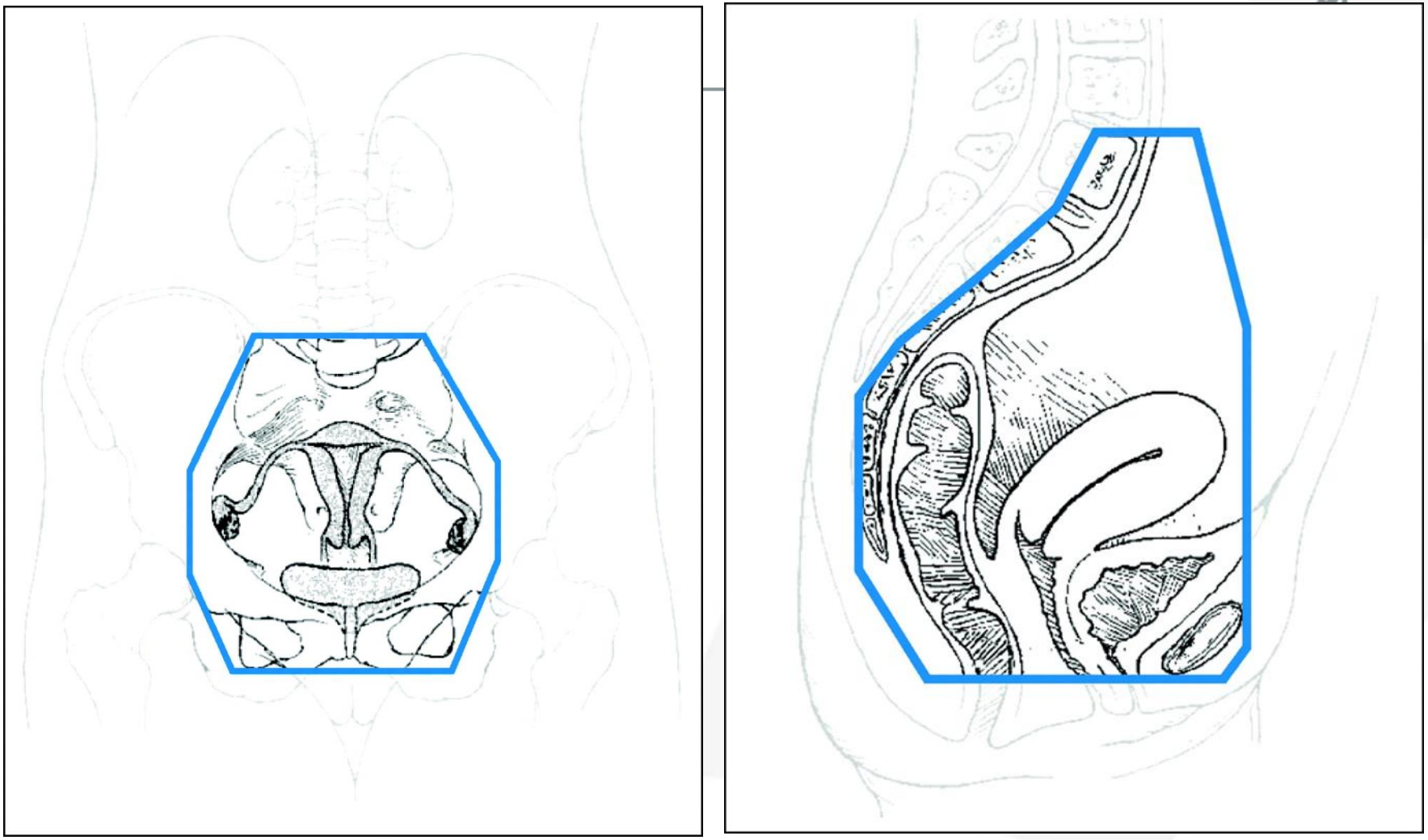

Monk, B. J. et al. J Clin Oncol; 25:2952-2965 2007

JOURNAL OF CLINICAL ONCOLOGY

Moving from 2-D to 3-D

- Risk of geographical miss of both primary and nodal areas
- Unnecessary irradiation of normal tissues: bladder, rectum, small bowel and bone marrow
- Gillian Thomas - Sunnybrook, Toronto
- 43 patients (retrospective analysis)
- Contoured vessels as a surrogate for nodes
- Conventional 2-D/virtual simulation borders

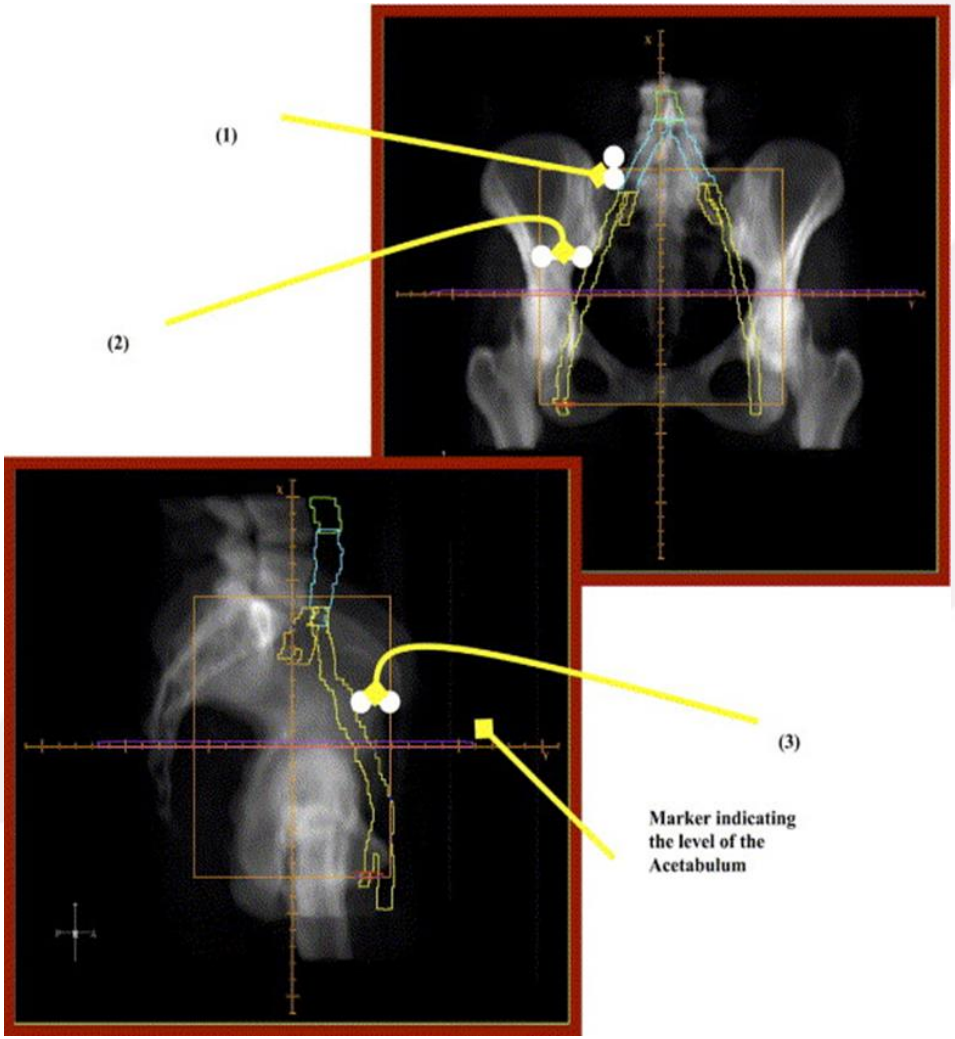

	Superior Border N (%)	Lateral Border AP Field N (%)	Anterior Border LAT Field N (%)
≥1 Vessel Outside Field	11 (25.6)	0 (0.0)	2 (4.6)
≥1 Inadequate Margin (<15 mm)	23 (53.5)	9 (20.9)	28 (65.1)
Both Margins Adequate (15-20 mm)	5 (11.6)	15 (34.9)	7 (16.3)
Both Margins Generous (>20 mm)	4 (9.3)	19 (44.2)	6 (14.0)

Finlay et al. Use of CT simulation for treatment of cervical cancer to assess the adequacy of lymph node coverage of conventional pelvic fields based on bony landmarks.

International Journal of Radiation Oncology*Biology*Physics, Volume 64, Issue 1, 2006, 205–209

Clearly the good old simulator is not enough ….

Development of 3-D techniques

Significant proportion have sub-optimal nodal coverage

Techniques to evaluate nodes

MRI with contrast USPIO (ultra small para-magnetic iron oxide)

>95% nodes covered by 7mm margin

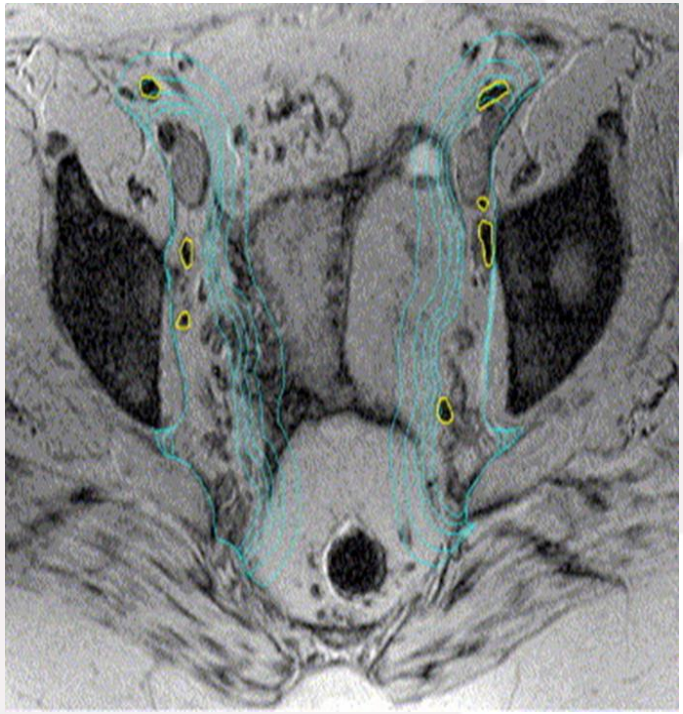

Taylor et al, Int J Rad Onc Biol Phys Vol. 63,No.5,pp 1604

Development of contouring guidelines

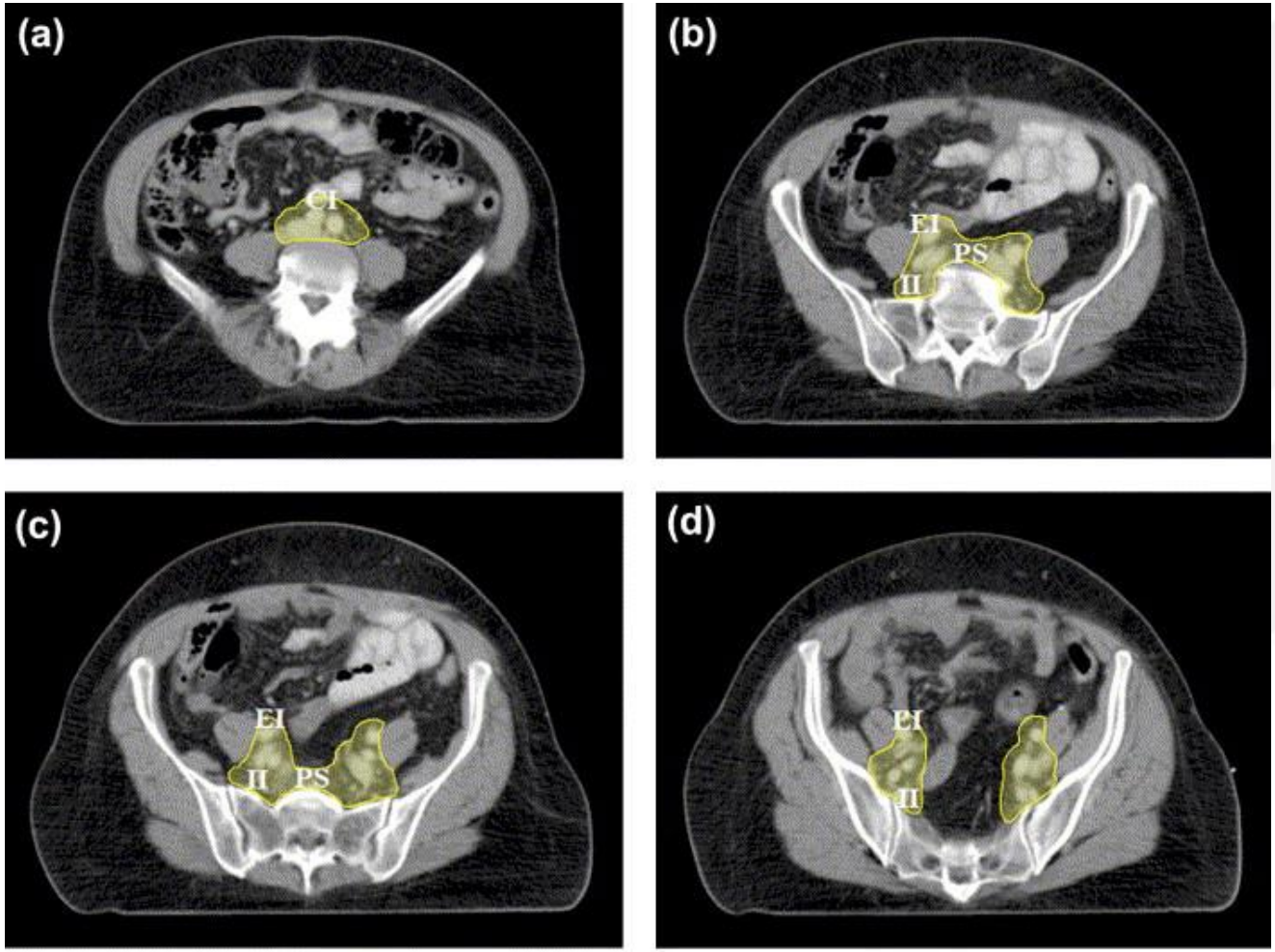

RTOG atlas

Consensus Guidelines for the Deliniation of the CTV in the Postoperative Pelvic Radiotherapy of Endometrial and Cervical Cancer

William Small Jr., M.D., Radiation Oncology *
Arno J. Mundt, MD, Radiation Oncology†

* Robert H. Lurie Comprehensive Cancer Center of Northwestern University.
† University of California San Diego

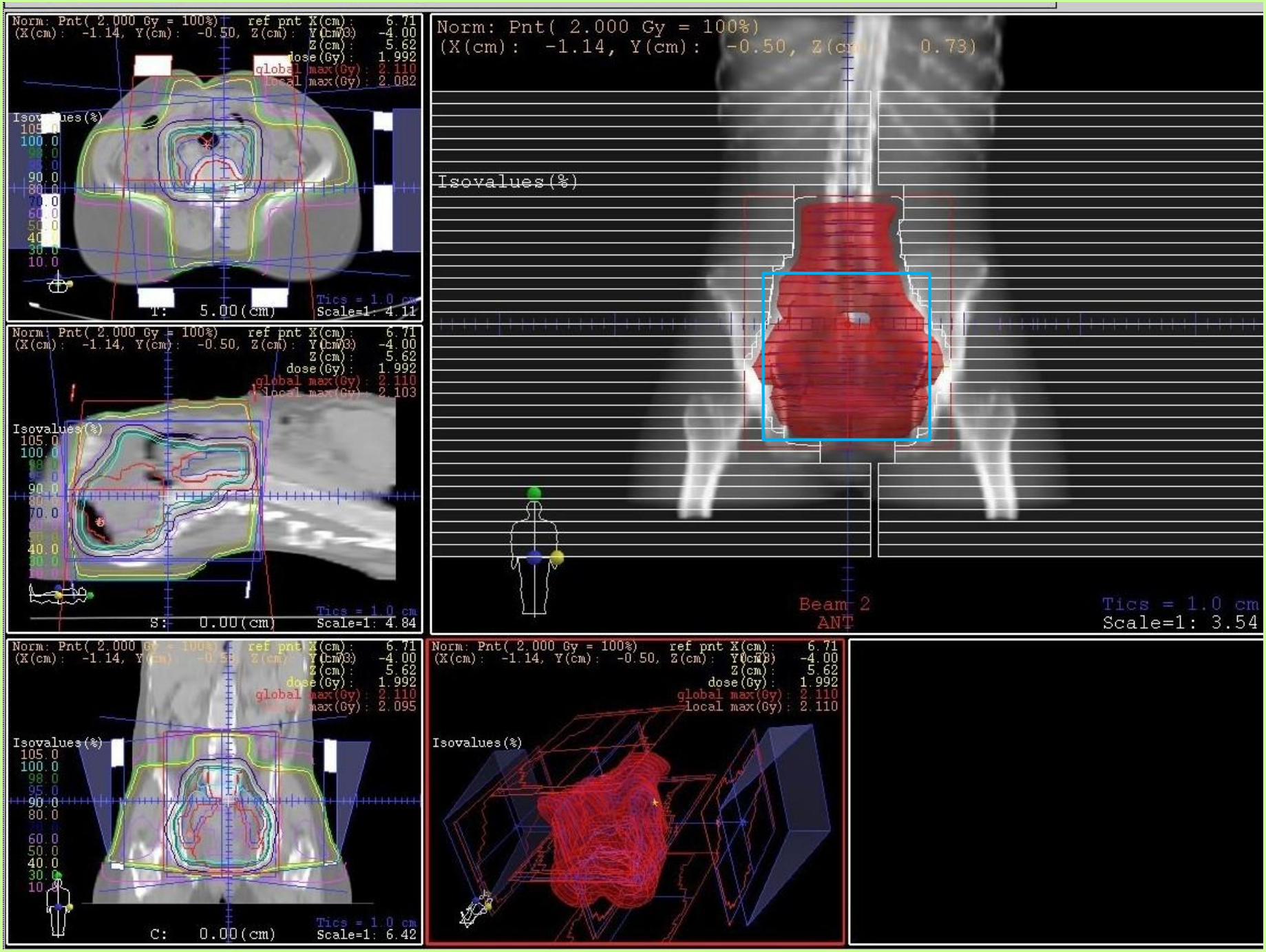
Norm: Pnt(2.000 Gy = 100%)
(X(cm): -1.14, Y(cm): -0.50, Z(cm): 0.73)
Isovalues(%)
Beam 2
ANT
Tics = 1.0 cm
Scale=1: 3.54
ref pnt X(cm): 6.71
Y(cm): -4.00
Z(cm): 5.62
dose(Gy): 1.992
global max(Gy): 2.110
local max(Gy): 2.082
T: 5.00(cm)
Scale=1: 4.11
local max(Gy): 2.103
S: 0.00(cm)
Scale=1: 4.84
local max(Gy): 2.095
C: 0.00(cm)
Scale=1: 6.42
local max(Gy): 2.110

Now we're getting somewhere……

What's the next step?

What about positive nodes ?

Can we reduce dose to OAR?

What about organ motion?

Rotational therapy/IMRT

1. Reduce dose to OAR
2. Boost involved nodes
3. Reduce treatment time
4. Plan of the day!

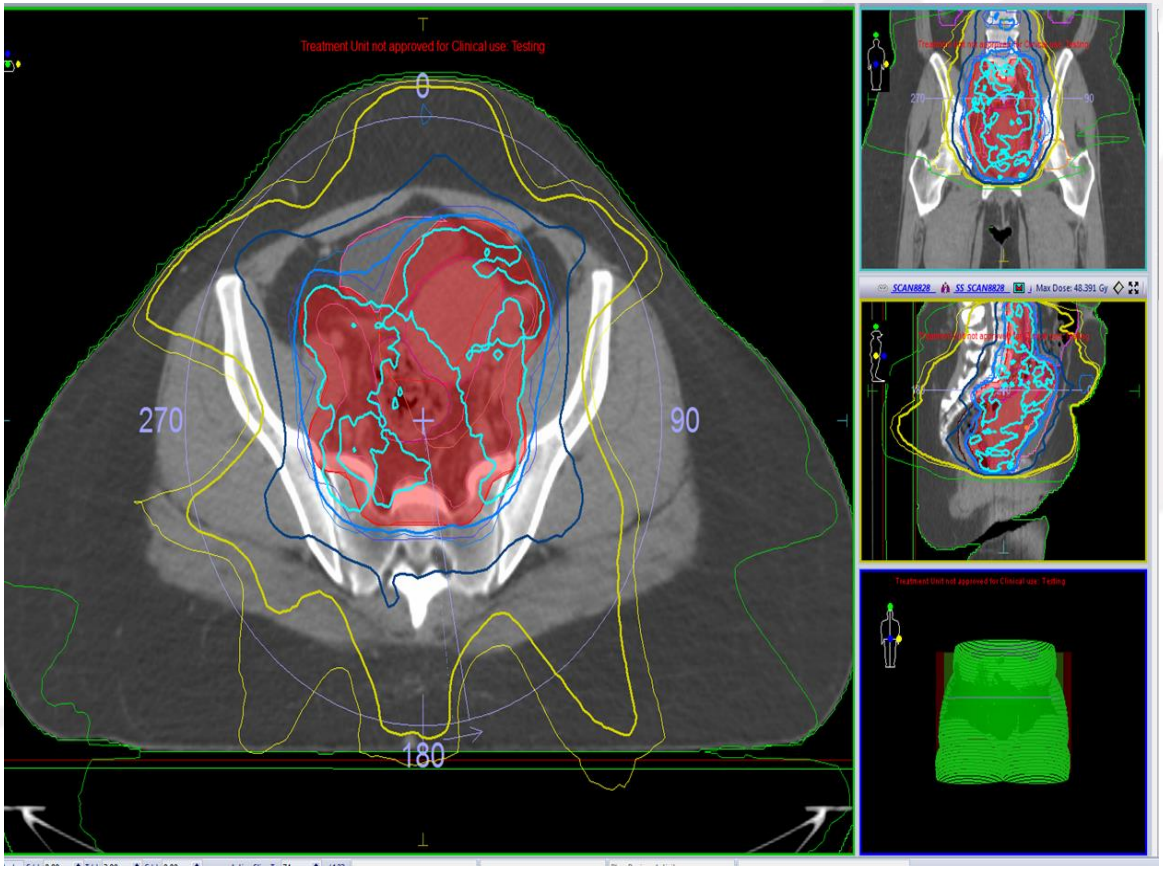

Plan of the day

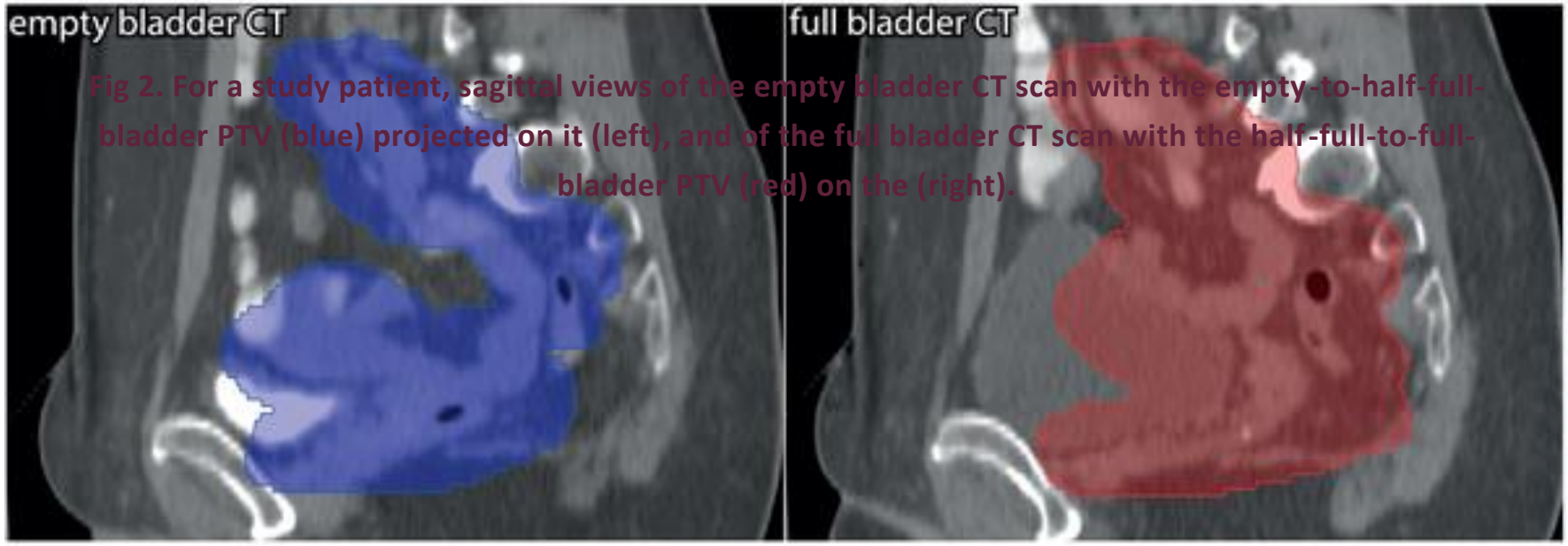

Fig 2. For a study patient, sagittal views of the empty bladder CT scan with the empty-to-half-full-bladder PTV (blue) projected on it (left), and of the full bladder CT scan with the half-full-to-full-bladder PTV (red) on the (right).

Sharfo AWM, Breedveld S, Voet PWJ, Heijkoop ST, Mens JWM, et al. (2016) Validation of Fully Automated VMAT Plan Generation for Library-Based Plan-of-the-Day Cervical Cancer Radiotherapy. PLOS ONE 11(12): e0169202. doi:10.1371/journal.pone.0169202
http://journals.plos.org/plosone/article?id=10.1371/journal.pone.0169202

Now this is real radiotherapy, finally I’m earning my money!

What more could I do?!

Improved imaging techniques –PET-CT

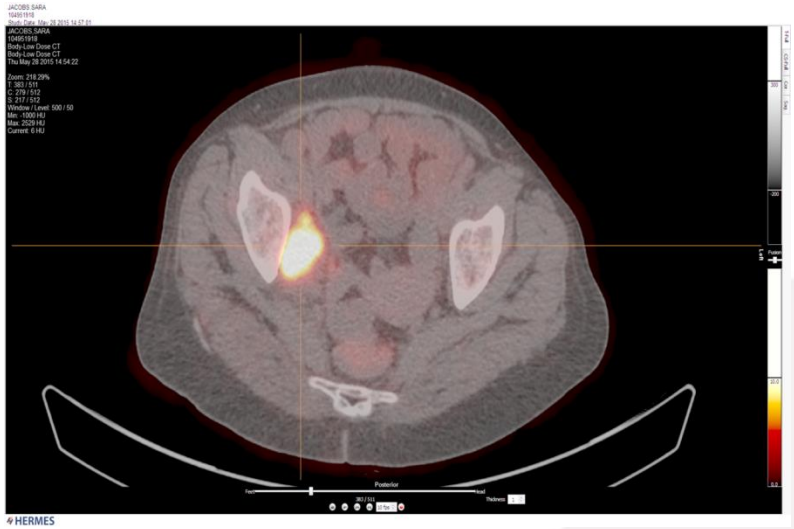

PET-CT planning integration

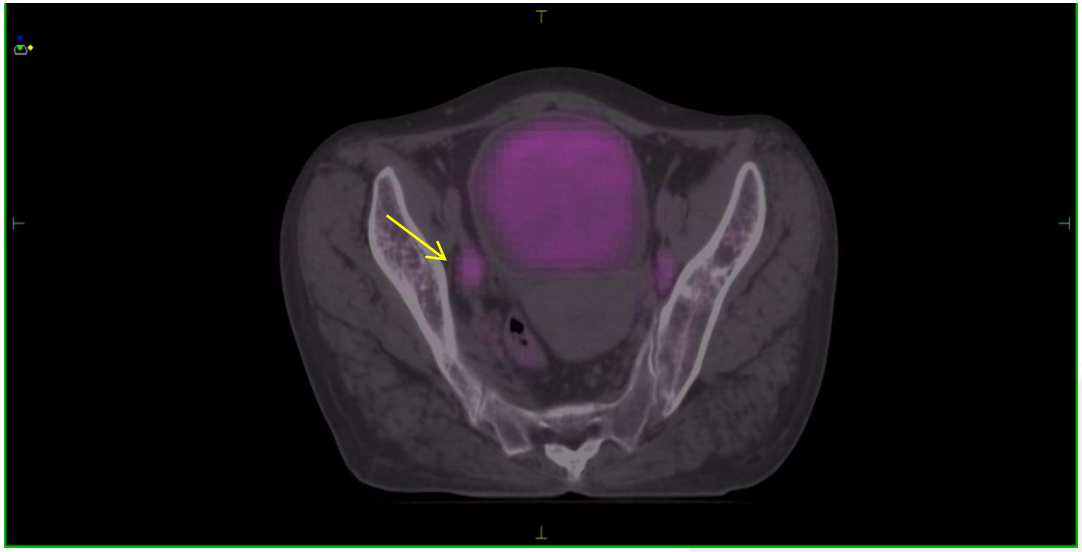

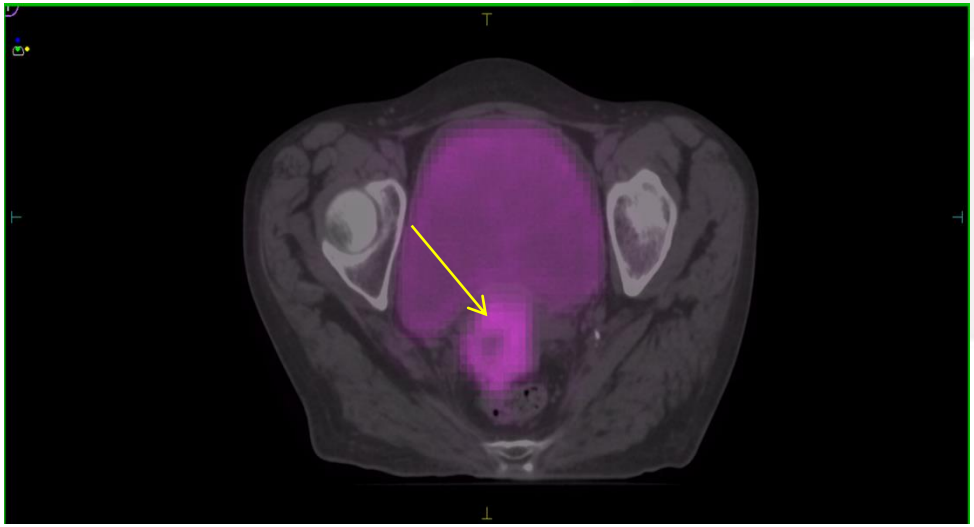

State-of-the-art advanced RT

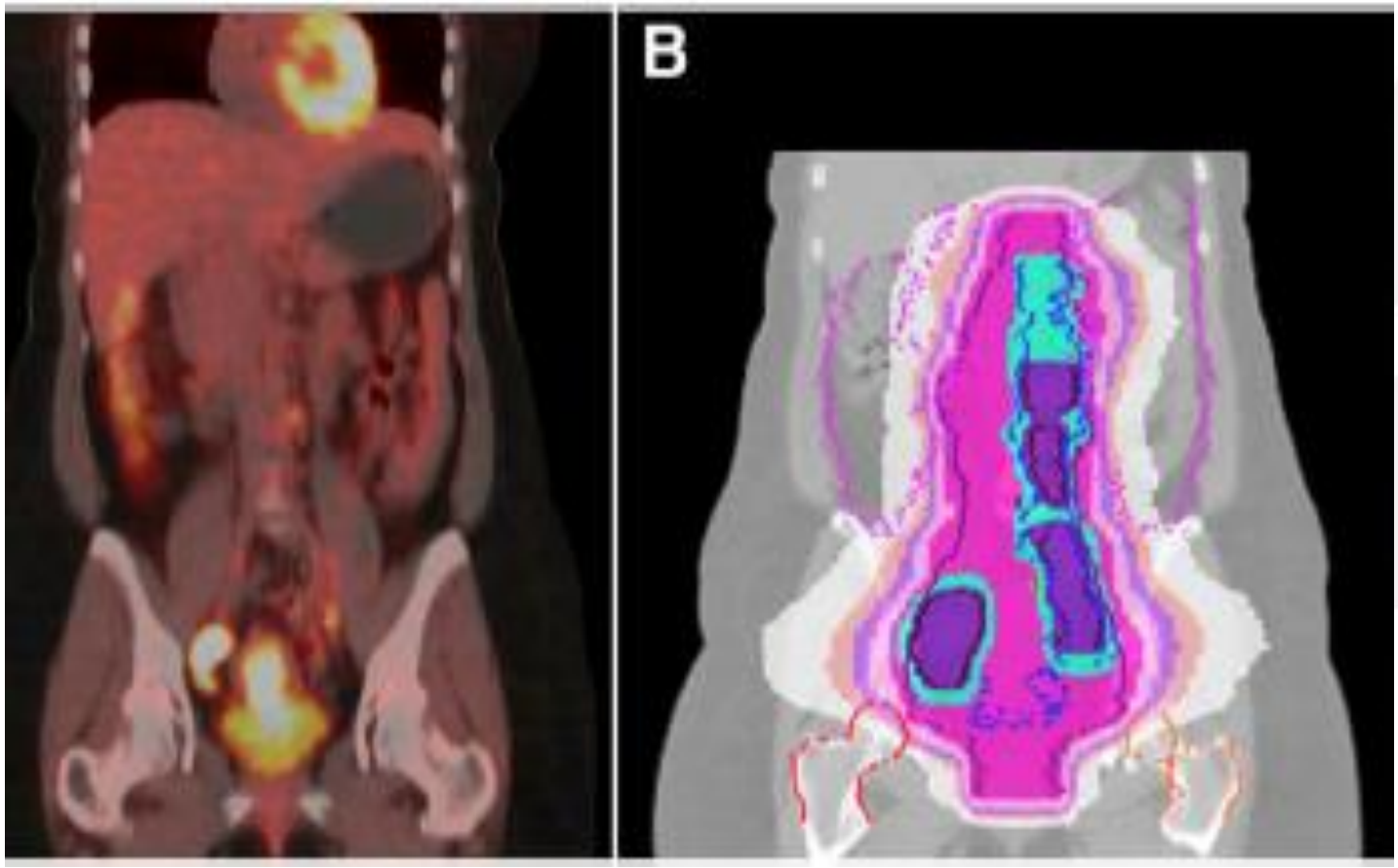

Benefits of advanced techniques

Accurate delivery of dose to a smaller volume

Reduced dose to bowel/rectum/bladder

Adaptive RT – rescan, replan

BUT -- Labour/resource/skill intensive

Brachytherapy

UNIVERSITEIT
STELLENBOSCH
UNIVERSITY

2-D brachytherapy

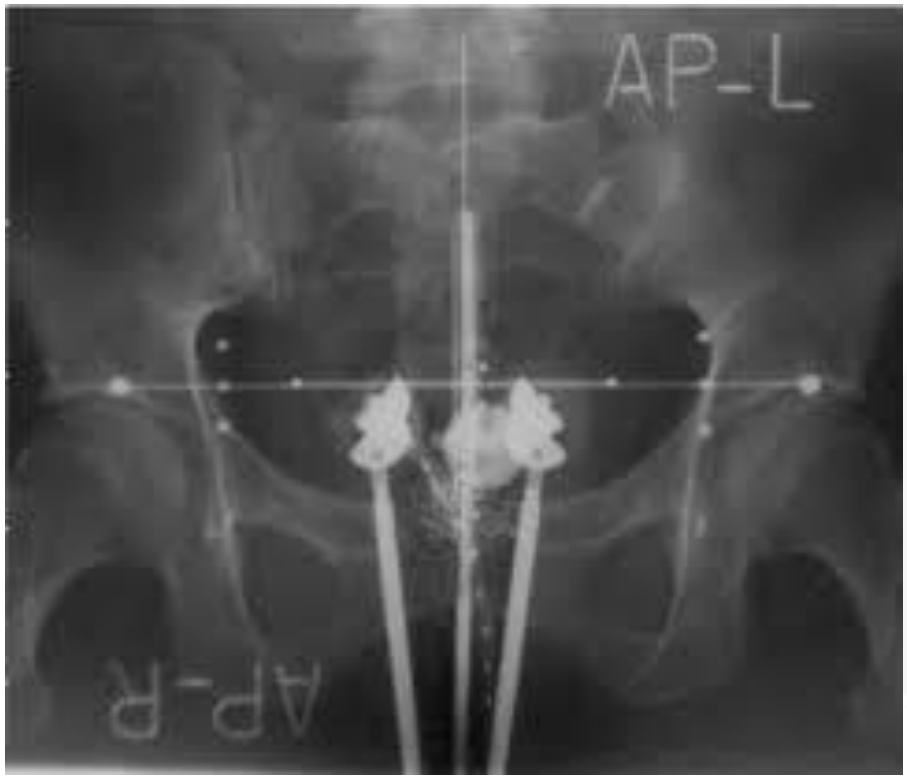

1950's

Caesium LDR

Iridium HDR

One size fits all

3-D Brachytherapy planning

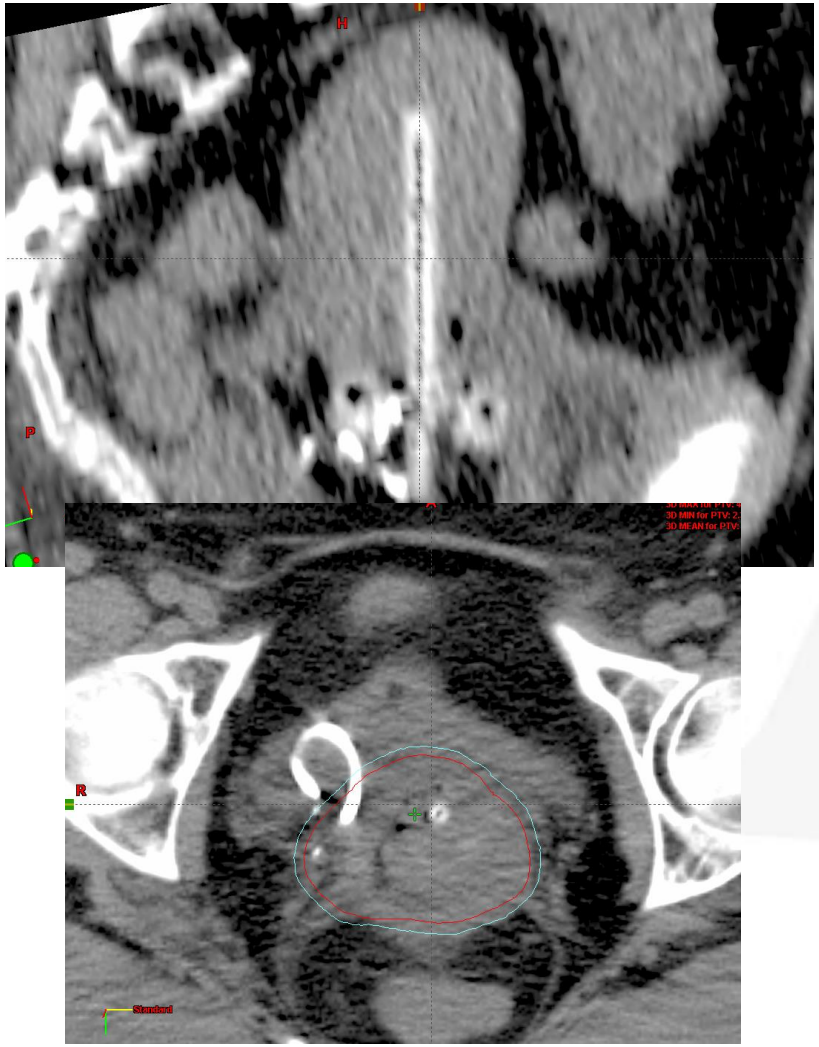

Championed by the Potter group from Vienna

MRI-based imaging and volumetric planning

Conformal planning of visible residual disease

GEC-ESTRO guidelines

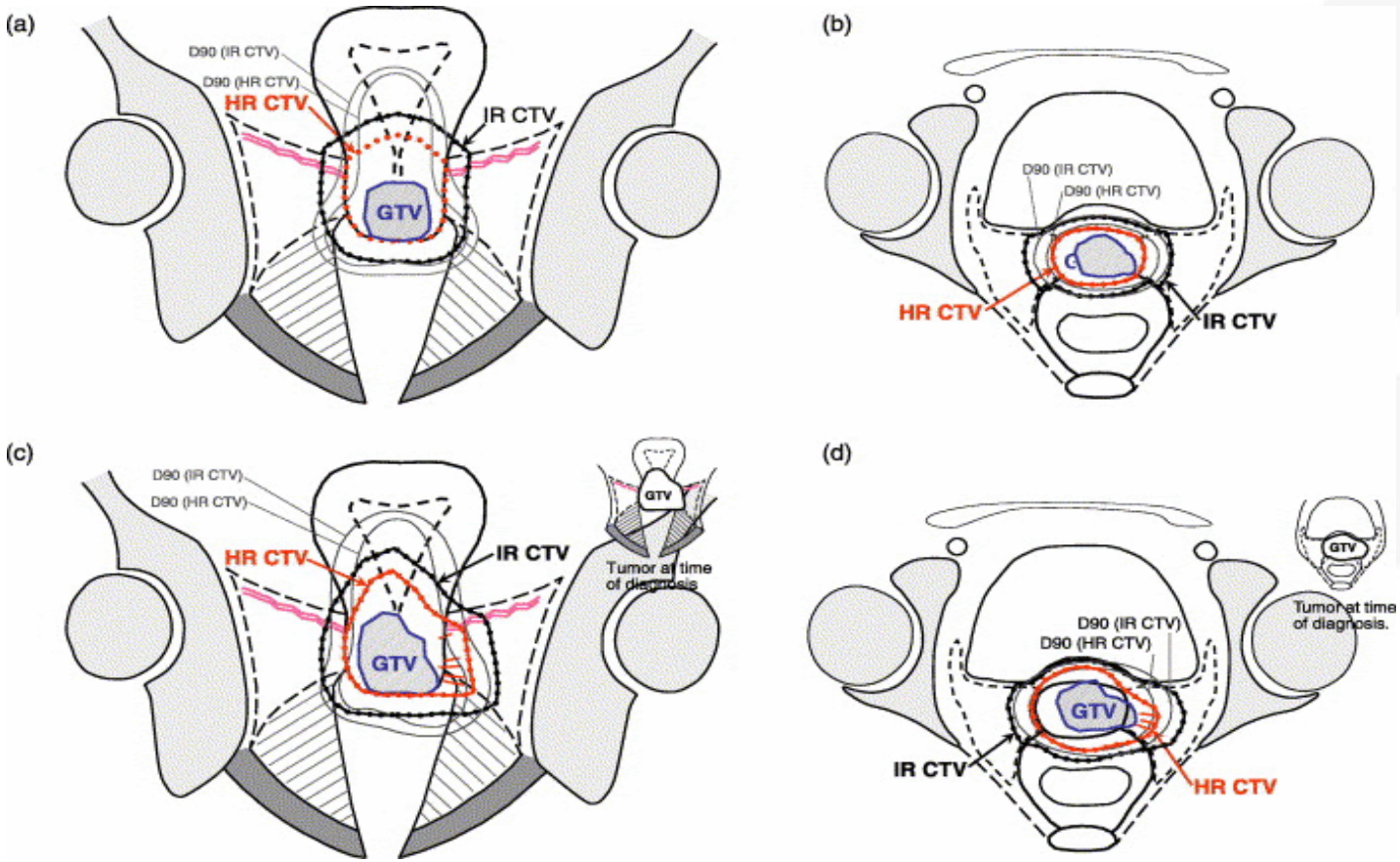

Is it worth all the effort???

retroEMBRACE

Radiotherapy and Oncology 120 (2016) 428–433

Contents lists available at ScienceDirect

Radiotherapy and Oncology

journal homepage: www.thegreenjournal.com

Image guided brachytherapy in cervical cancer

Image guided brachytherapy in locally advanced cervical cancer: Improved pelvic control and survival in RetroEMBRACE, a multicenter cohort study

Alina Sturdza [a], Richard Pötter [a,*], Lars Ulrik Fokdal [b], Christine Haie-Meder [c], Li Tee Tan [d], Renaud Mazeron [c], Primoz Petric [e], Barbara Šegedin [e], Ina Maria Jurgenliemk-Schulz [f], Christel Nomden [f], Charles Gillham [g], Orla McArdle [g], Erik Van Limbergen [h], Hilde Janssen [h], Peter Hoskin [i], Gerry Lowe [i], Ekkasit Tharavichitkul [j], Elena Villafranca [k], Umesh Mahantshetty [l], Petra Georg [a], Kathrin Kirchheiner [a], Christian Kirisits [a], Kari Tanderup [b], Jacob Christian Lindegaard [b]

Methods/results

- 12 institutions
- Retrospective observational study
- Jan 1998- August 2012
- Primary endpoint- local control (cervix)
- Secondary endpoints
  - Pelvic control
  - OS
  - CSS
  - Toxicity

- 731 patients
- 19.8% IIIb
- Mean D90 HR-CTV 87Gy

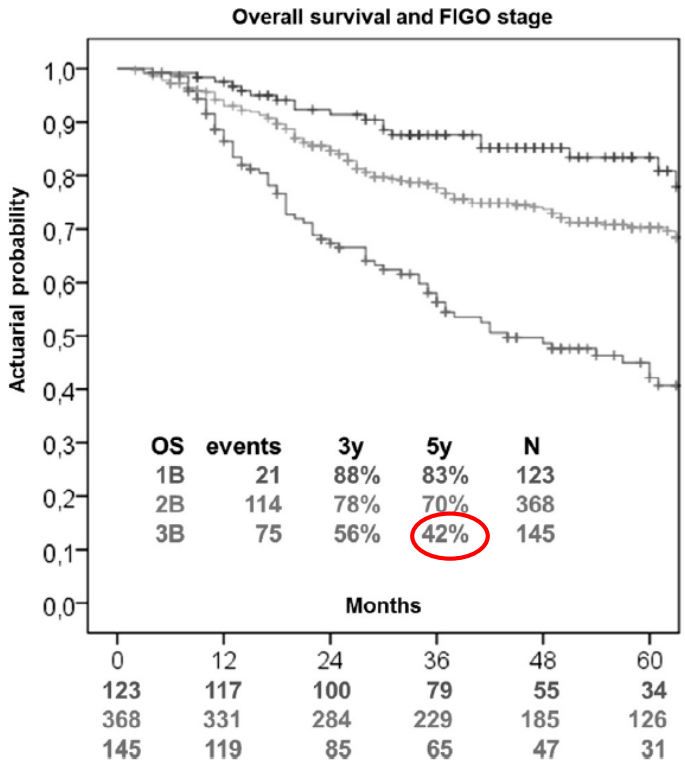

Fig. 4. Actuarial Kaplan–Meier estimates for stage related overall survival (OS) in patients with stage IB, IIB, IIIB disease ($n = 636$). Absolute number of events and actuarial estimates for outcome at 3 and 5 years are indicated.

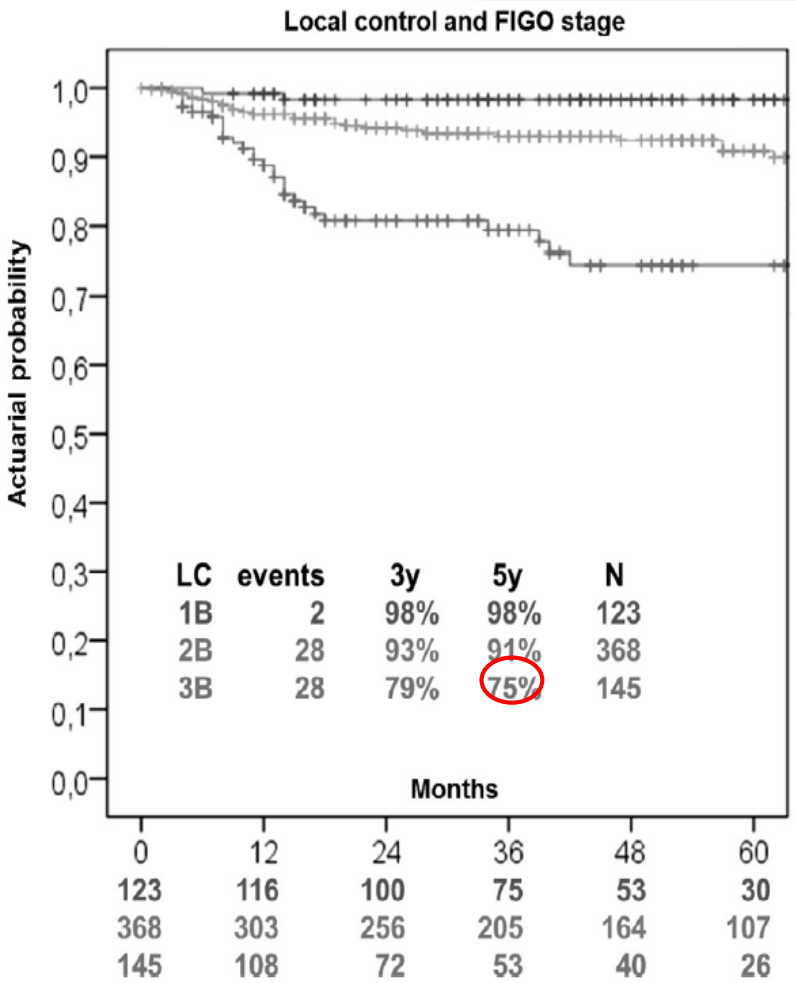

Fig. 2. Actuarial Kaplan–Meier estimates for stage related local control (LC) in patients with stage IB, IIB, IIIB disease ($n = 636$). Absolute number of events and actuarial estimates for outcome at 3 and 5 years are indicated.

EMBRACE

Radiotherapy and Oncology 120 (2016) 412–419

Contents lists available at ScienceDirect

Radiotherapy and Oncology

journal homepage: www.thegreenjournal.com

Image guided brachytherapy in cervical cancer

Dose–volume effect relationships for late rectal morbidity in patients treated with chemoradiation and MRI-guided adaptive brachytherapy for locally advanced cervical cancer: Results from the prospective multicenter EMBRACE study ☆

Renaud Mazeron [a,*], Lars U. Fokdal [b], Kathrin Kirchheiner [c], Petra Georg [c], Noha Jastaniyah [c], Barbara Šegedin [d], Umesh Mahantshetty [e], Peter Hoskin [f], Ina Jürgenliemk-Schulz [g], Christian Kirisits [c], Jacob C. Lindegaard [b], Wolfgang Dörr [c], Christine Haie-Meder [a], Kari Tanderup [b], Richard Pötter [c], on behalf of the EMBRACE collaborative group [1]

METHODs/ Results

24 centres worldwide

Institutional EBRT and chemo regimen

MRI based HDR and LDR brachytherapy

Prospective collection of DVH information and evaluated toxicity 3-60 months

960 evaluable patients

Bottom line = **significant increase of Grade 2-4 toxicity if mean dose to the rectum increased**.

$D2cc^3$ > 75 Gy increased severe morbidity e.g. fistulae

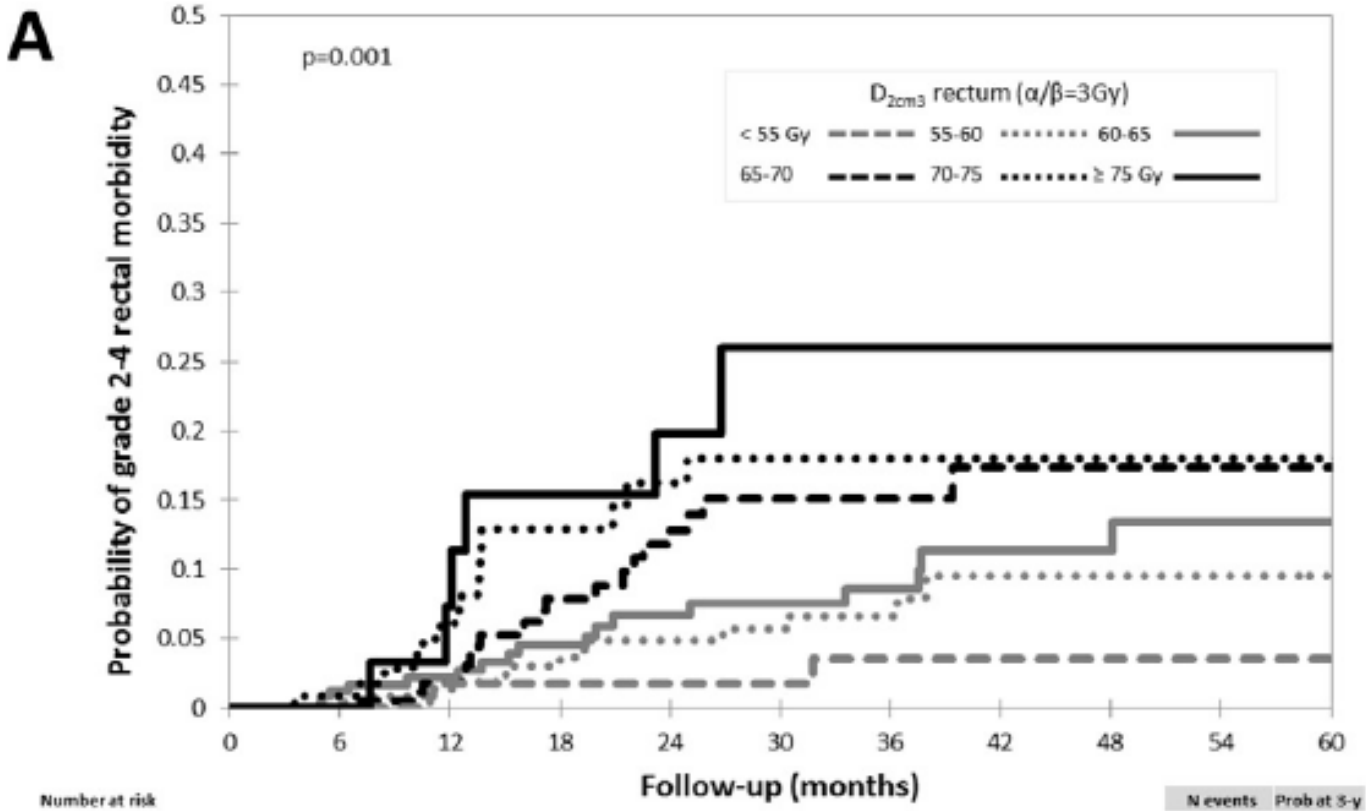

Number at risk						N events	Prob at 3-y
< 55 Gy	129	107	77	52	28	3	3.5%
55 - 60	242	198	129	75	44	13	7.9%
60 - 65	243	185	115	79	44	17	8.6%
65 - 70	196	145	86	52	28	19	15.1%
70 - 75	115	88	49	32	16	15	18%
≥ 75 Gy	35	24	18	11	3	6	26%

Benefits of 3-D brachytherapy

- Accurate target definition – including residual areas in the parametria
- Record and reduce dose to the rectum to avoid late events
- Improve local control
- Overall survival?
- BUT - Labour/ resource/ skill intensive

So what?

UNIVERSITEIT
STELLENBOSCH
UNIVERSITY

What would I do if …..

I had a Cobalt and no simulator

Clinical mark-up from the iliac crests to the vulva

If I had a simulator

Treat generous margins from the top of L4 to the bottom of the bony obturator

If I had a CT

Virtual simulation using templates but checking my anatomy

Cervical cancer palliative RT

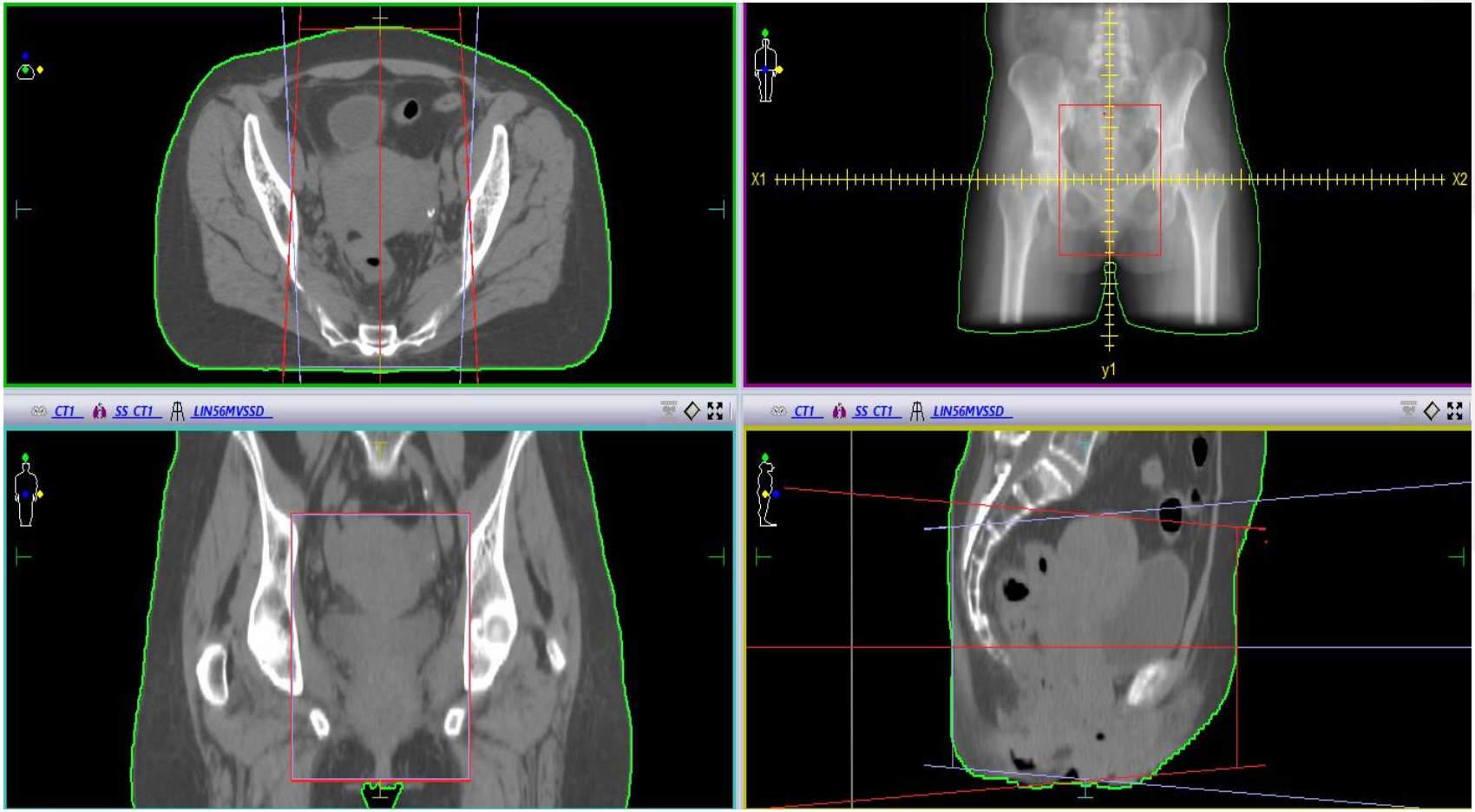

Vulva Cancer palliative RT

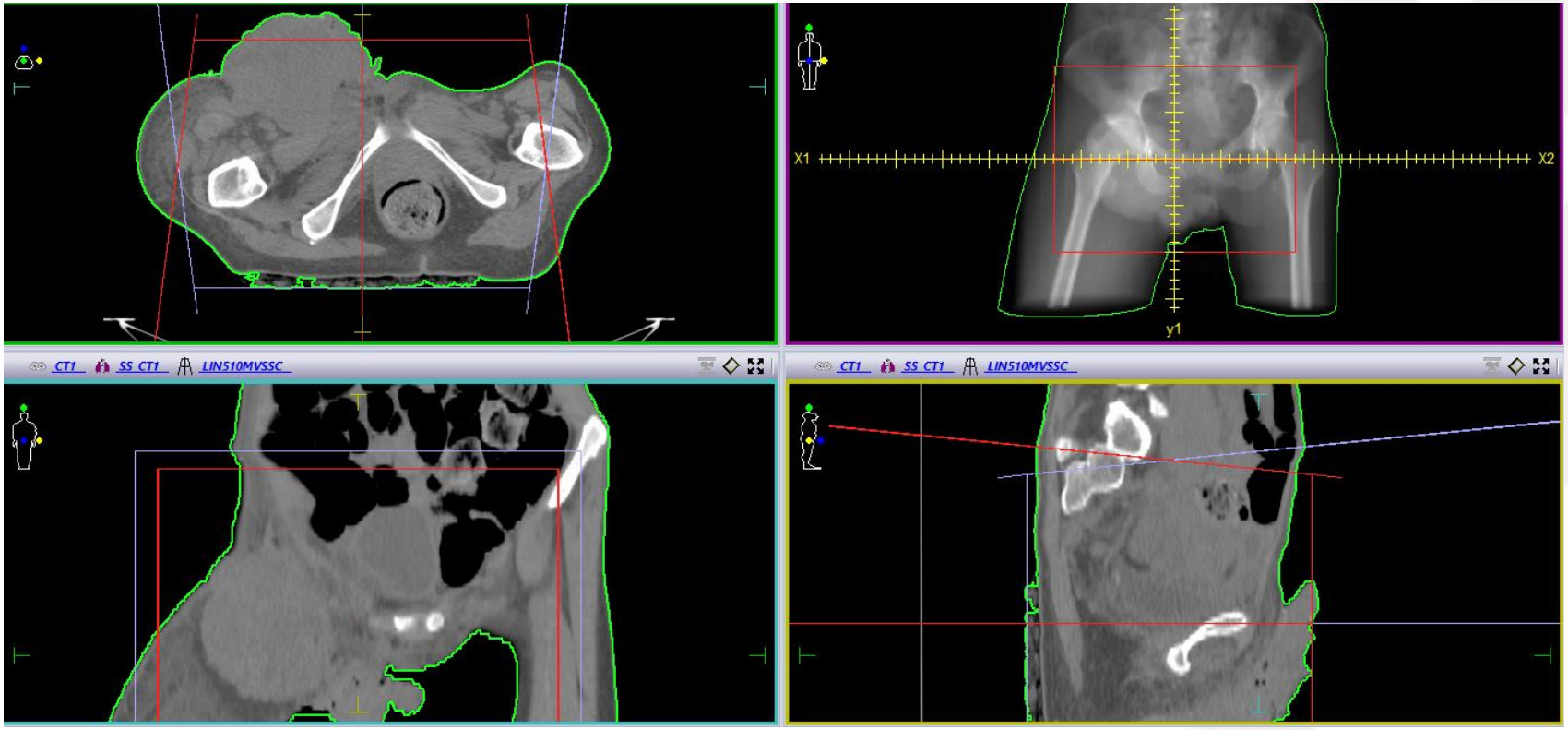

What would I do if …..

I had a Cobalt and no simulator

Clinical mark-up from the iliac crests to the vulva

If I had a simulator

Treat generous margins from the top of L4 to the bottom of the bony obturator

If I had a CT

Virtual simulation using templates but checking my anatomy

If I had a CT planning system

Follow the RTOG contouring guidelines and do a decent 3-D plan

If I had a PET-CT

Use the information to modify my contours

What would I do if….

- If I had a CT-planning system, PET-CT, VMAT, 10 physicists and 1 patient per week
  - A VMAT plan-of-the-day and MRI-guided 3-D HDR brachytherapy!
  - And have a lot of time to drink tea….

Conclusions

- Significant advances in the last 10-15 years in the management of gynaecological radiotherapy patients
- Highly accurate techniques
- Cost –time/ expertise/ infrastructure
- Reality – well-planning 2-D radiotherapy still saves the most lives of cervix cancer patients on the continent