GOOD SCIENCE
BETTER MEDICINE
BEST PRACTICE

European Society for Medical Oncology

ESMO Preceptorship Programme

Dr Oana Chebac.
Acute Oncology Service
University Hospital Southampton NHS Foundation Trust

Pembrolizumab. Case report

Case report

- Male, caucasian, 68 years old, PS=0
- PMH: DM diet controlled, GERD, vitiligo, HTN, IHD (stents: 2006, 2014)

- **14/02/2012** diabetic retinopathy screening: supero-temporally RE 15x12 mm pigmented choroidal mass, VA 6/6 RE, VA 5/6 LE (symptoms: blurred vision R eye, scotoma)
- **March 2012**: PET CT -NAD
- **20/04/2012** primary enucleation pT4aN0M0
  - histology : extrascleral extension
  - cytogenetic: monosomy 3 and gain chromosome 8q
- Adj RT R orbit 50Gy/20# / 4 weeks
- Surveillance : 6 months LFTs, liver USS
- **08/04/15** Liver MRI: isolated single metastasis
- **27/04/15** PET CT :increased FDG left fifth rib; no FDG avid hepatic lesion
- **01/12/15** PET CT : small volume liver metastasis, diffuse bony metastatic disease
  - **LDH=554**, ALT=10, Br=16, ALP=118, TP=70, Alb=32

PET CT
23/04/2015

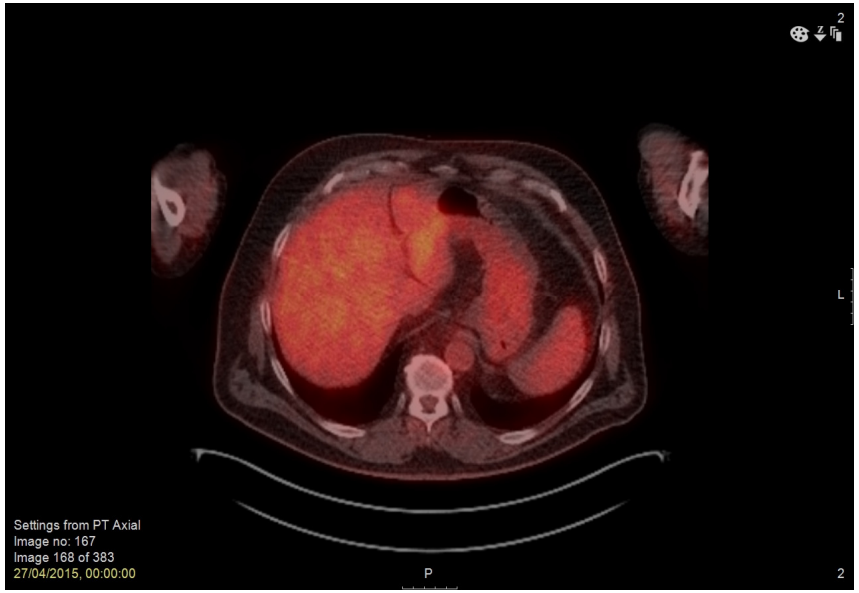

PET CT
27/11/2015

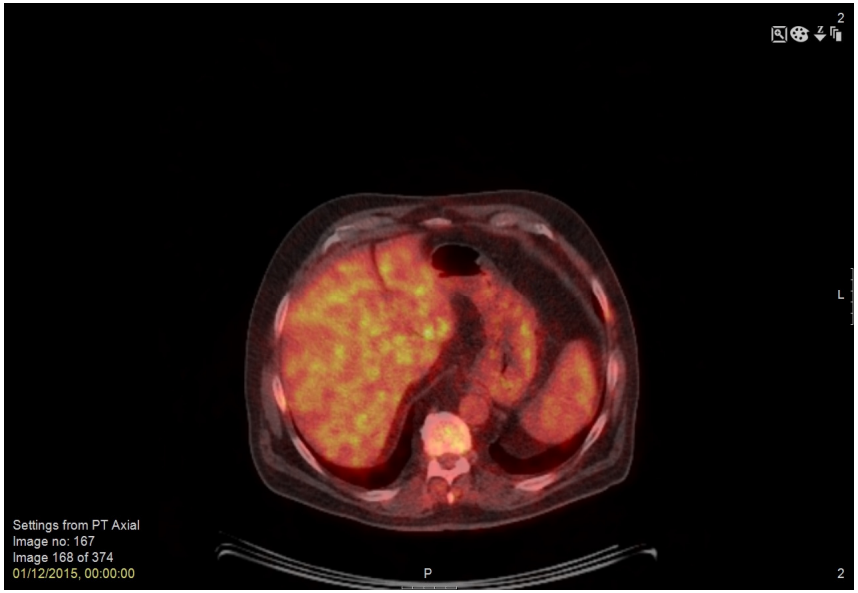

Pembrolizumab 2 mg/kg every 3 weeks, 3 cycles + Denosumab 120 mg s/c

- c1 18/12/2015
  - Alb=32, ALP=122, Alt=11, Br=7, **LDH=836**, CRP=39,
- c2 08/01/16
  - Alb=26, ALP=147, ALT=27, Br=6, GGT3=116, **LDH=704**, CRP..
- c3 29/01/16
  - Alb=26, **ALP=204**, **ALT=62**, Br=14, **GGT3=117**, **LDH=1913**
- c4 ….

Admission post 3rd cycle:

- **Symptoms**: **dyspnea** 3/52 **grd 2** CTCAE v4.03; sensation tight chest
  - BP=110/50, SpO=94%RA , RR=20, pulse=70, RR=22, Temp=36.4
  - Auscultation: L basal crep +pericardial rub
  - ECG: NSR
  - **TnT=915**, **ALT=74**, Br=8, Alb=27, **ALP=197**, CRP=54, **LDH=1385**
  - CTPA : no pulmonary embolism/ pneumonitis; left 5th rib pathological fracture and abnormal bony texture/sclerosis
  - Echo 02/02/2016: Mild aortic regurgitation, mild LV systolic impairment with generalised hypokinesia; EF 50-55%

- **Cardiology input:** ?NSTEMI/ myocarditis Aspirin+ Clopidogrel 3/12, stress cardiac MRI, ISMN MR 25mg od
- **NO steroids started**
- **18/02/16** cardiac MR: acute myocarditis; normal LV size, LVEF 59%,
  - new widespread multifocal hepatic and thoracic vertebral metastasis (extra-cardiac findings)
- **Clinical deterioration** despite initiation of steroids treatment (stopped); due to disease progression

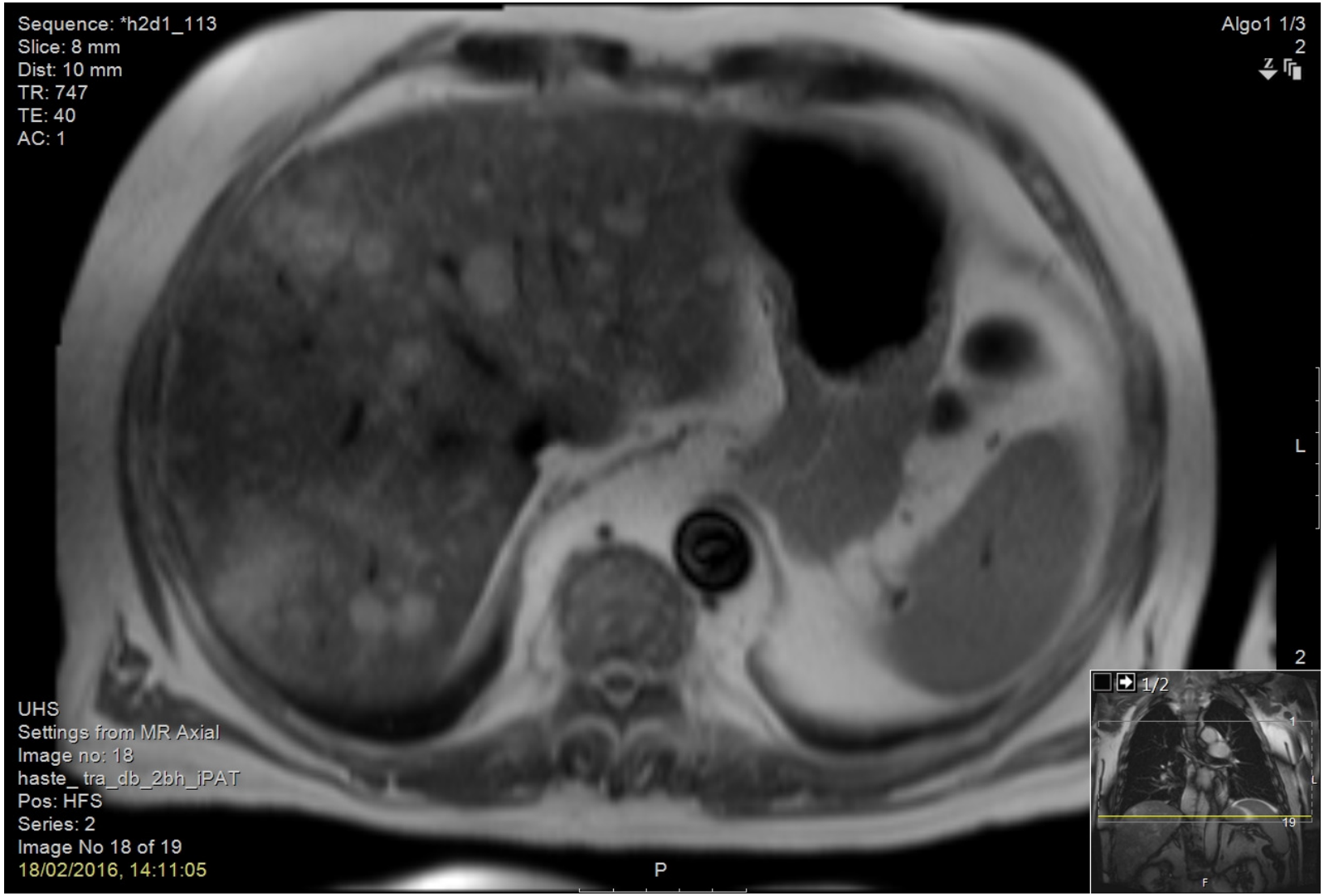
Sequence: *h2d1_113
Slice: 8 mm
Dist: 10 mm
TR: 747
TE: 40
AC: 1
Algo1 1/3
2
L
2
UHS
Settings from MR Axial
Image no: 18
haste_ tra_db_2bh_iPAT
Pos: HFS
Series: 2
Image No 18 of 19
18/02/2016, 14:11:05
P
1/2
1
19
F

Sequence: *tfi2d1_15
Slice: 6 mm
TR: 44.1
TE: 1.24
AC: 1
Algo1 1/3
6
Comments: RR 866 +/- 4; 8 heartbeats
L
UHS
Image no: 1
tf2d15_retro_cine_4ch
Pos: HFS
Series: 6
Image No 1 of 25
18/02/2016, 14:13:07
PH
6

Uveal melanoma (UM). Immunotherapy

- specific algorithms for identification, early intervention, management of ir AEs
- development of biomarkers for autoimmune toxicity
- efficacy of anti-PD1 agents/immunotherapy in UM vs CM (cutaneous melanoma)
- genetic profile UM vs CM: lower degree of aneuploidy, genomic instability, mutational load