Preceptorship on Prostate Cancer
16-17 October 2014, Lugano, Switzerland

Abiraterone withdrawal syndrome in metastatic castration resistant prostate cancer

M.D. Antonello Veccia
Medical Oncology
Santa Chiara Hospital, Trento, Italy

Case report

Time	Event	Treatment	Result
1995	Diagnosis of prostate adenocarcinoma (Gleason score 6:3+3), cT3 N0 M0 stage in a 59-yr-old man	External radical radiotherapy (76 Gy)	Complete response
1997	Biochemical failure	Oct 1997 - Dec 2008 Intermittent LHRH agonist therapy	Disease control
Dec 2008	Biochemical and radiographic (bone) PD	Dec 2008 - Aug 2009 Bicalutamide	Transient biochemical response
Aug 2009	Biochemical and radiographic PD	Antiandrogen withdrawal	No response

Time	Event	Treatment	Result
Dec 2009	Biochemical and radiographic PD	Dec 2009 – Jan 2011 LHRH agonist therapy	Mild disease control
Feb 2011	Biochemical and radiographic PD	Feb 2011 - Apr 2011 Weekly Docetaxel chemotherapy for 3 courses	Short lasting response
Jul 2012	Biochemical (PSA 179 ng/mL) and radiographic PD (new bone and nodal lesions on choline PET/CT)	Abiraterone 1000 mg/die + prednisone 5 mgx2/die + ongoing LHRH agonist therapy	Good and long-lasting disease control

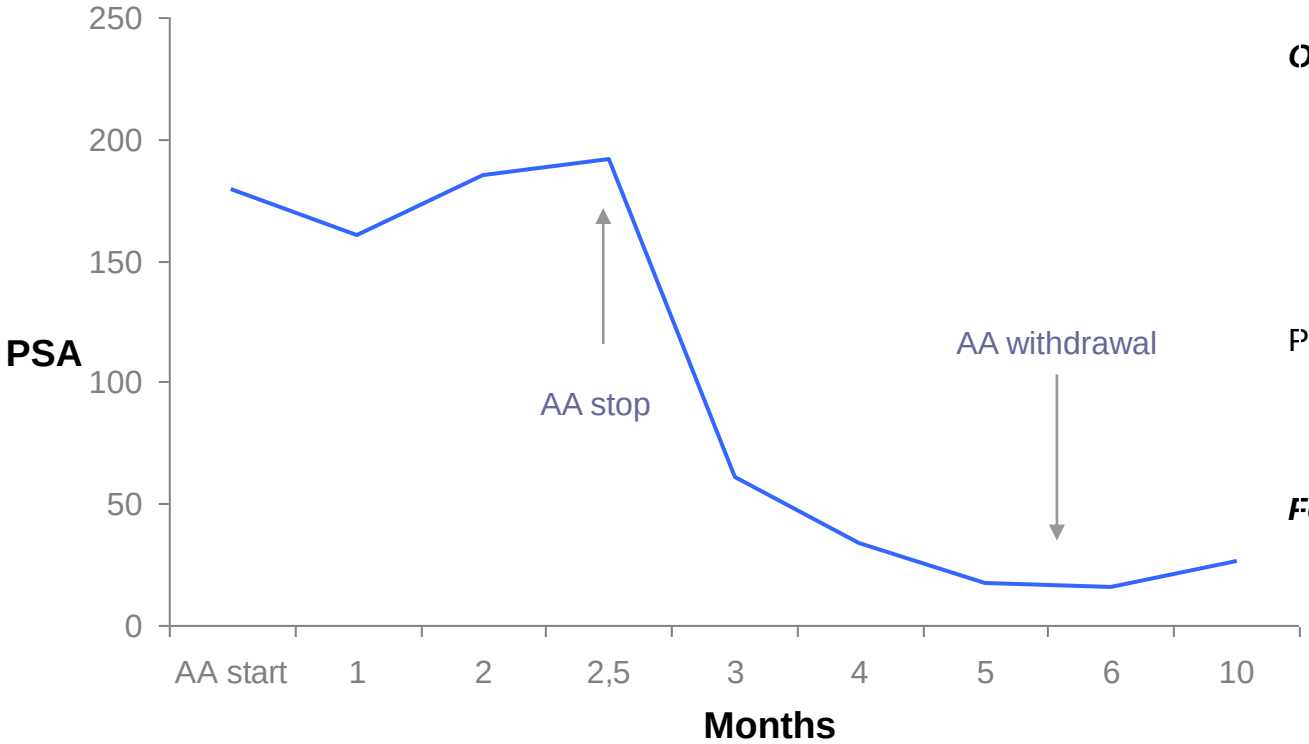

Oct 2012 Biochemical (PSA 192 ng/mL) and radiographic (mixed metabolic response, SUV increased in some lesions, decreased in others) PD → ***Abiraterone and concomitant prednisone withdrawal***

Progressive reduction of PSA value: 62 ng/mL (*Nov 2012*) and 16 ng/mL (*Feb 2013*)

Feb 2013 Choline PET/CT: bone and nodal SD with good metabolic response (SUV -35%)

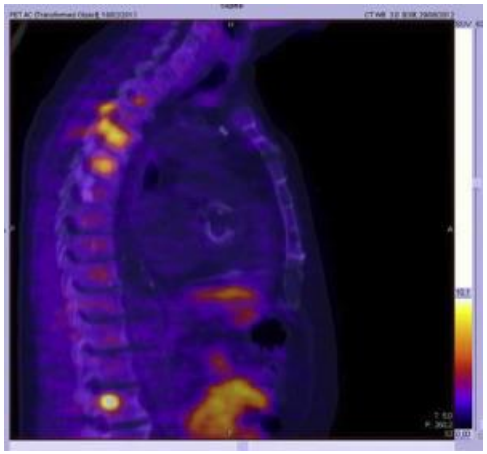

Aug 2012 **AA start**

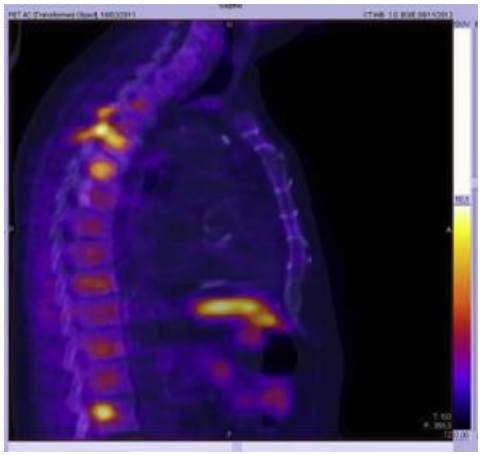

Oct 2012 **AA stop**

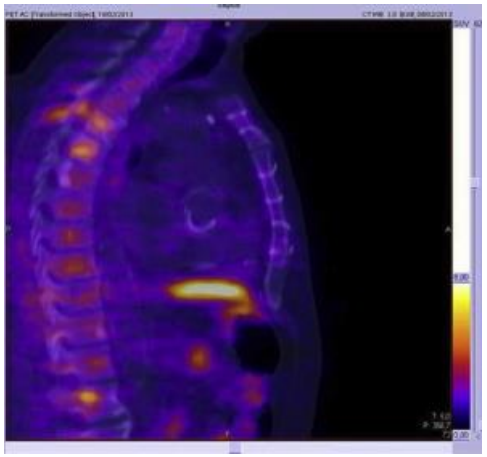

Feb 2013 **AA withdrawal**

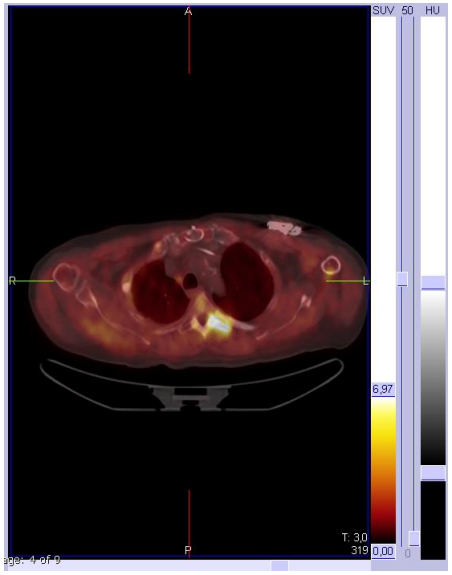

Jul 2013
AA restart

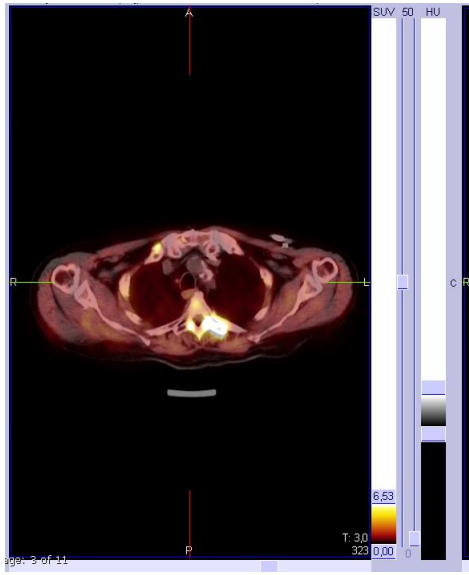

Oct 2013
AA stop

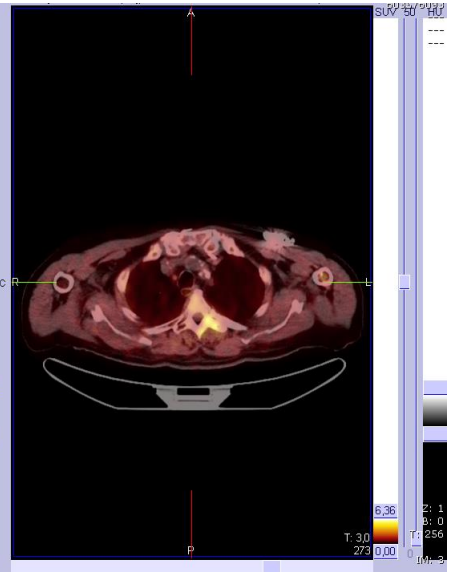

Feb 2014
AA withdrawal

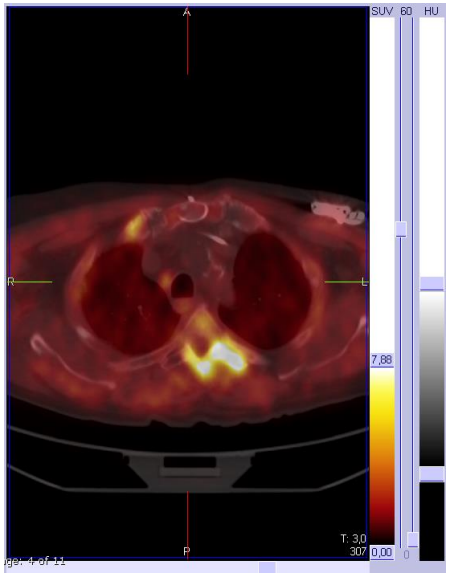

Jul 2014
AA restart

Conclusions

- Abiraterone withdrawal represents a new clinical condition but it needs to be further investigated (few cases in literature, reported in last 2 yrs)
- Clinical features similar to antiandrogen withdrawal
- Possible transient biochemical response and/or clinical/radiological improvements that are very important in the therapeutic strategy
- Molecular mechanisms are still poorly understood (effects on AR pathway?)
- Abiraterone withdrawal may become more frequent with the use of the drug in chemotherapy-naïve patients
- Abiterone qualifies uniquely for effective intermittent androgen deprivation of CRPC

Thank you for your attention!

E-mail: antonello.veccia@apss.tn.it